

The Role of Fermented Milk Containing Probiotic, Dandelion as Prebiotic or their Combination on Serum Metabolites, Enzymes, Testosterone and Testicular Histopathology of Arsenic-Intoxicated Male Rats

Mona A. Al-Damegh¹, Moustafa M. Zeitoun^{2,*} and Ahmed M. Abdel-Salam³

¹Department of Biology, College of Science and Arts, Qassim University, P.O. Box 5380, Onizah 51911, KSA

²Department of Animal Production and Breeding, College of Agriculture and Veterinary Medicine, Qassim University, P.O. Box 6622, Buraidah 51452, KSA

³Department of Food Sciences and Human Nutrition, College of Agriculture and Veterinary Medicine, Qassim University, P.O. Box 6622, Buraidah 51452, KSA

Abstract: This study aimed at investigating the ameliorative effects of probiotic and/or dandelion aqueous extract to reducing the risk of arsenic (As) intoxication on male rats. Fifty rats were randomly allotted into five groups, group 1 (C-) given regular diet and water daily for 56 days, group 2 (C+) given sodium arsenate in drinking water, group 3 (PRO) given sodium arsenate in addition to probiotic, group 4 (PRE) given dandelion aqueous extract plus sodium arsenate (prebiotic) and group 5 (SYN) given sodium arsenate plus probiotic/dandelion extract (synbiotic). At the experiment conclusion rats were sacrificed and blood and testes were collected and taken for analysis and histopathological study, respectively. Glutathione-S-transferase (GST), Alanine aminotransaminase (ALT) and Aspartate aminotransaminase (AST) activities and creatinine, triglycerides (TG) and testosterone (T) concentration were determined and testes histopathology was studied. Creatinine, AST and TG were lower ($P < 0.01$) in PRO, PRE and SYN compared with C+ rats. Arsenic ingestion didn't change rats body weight, but tended to increase testes weight. Also, there found decreases ($P < 0.05$) in testosterone in C+, PRE and SYN-rats, however coadministration of PRO to C+ rats alleviated the toxic effects resulting in a comparable testosterone level to C- rats. Histopathological sections of C+ testes showed dislocation of germinal cells, losing normal architecture, filling seminiferous tubules lumens with cellular debris, slight congestion of blood vessels and thickening of the interstitial tissue. Moreover, in PRE animals, testis showed spermatogenic cells losing their normal architecture with vacuulations and increased Leydig cells size. In PRO animals, the testes showed normality of most seminiferous tubules and normal spermatogonia, close to the C- rats. Testes of SYN rats showed little changes in spermatogenic cells structure. In conclusions, the protection of testicular toxicity and liver and kidney functions in arsenic-exposed rats is possible with probiotic or combined coadministration of dandelion-containing probiotic, but not with dandelion extract itself.

Keywords: *Traxacum officinalis*, arsenic toxicity, rats, probiotics, testis histopathology.

1. INTRODUCTION

The functional foods and bioactive components in foods take a lot of most attention and interesting field for food scientists, nutritionists and wide number of consumers. A functional food have a various physiological benefits, and can reduce the risk of chronic diseases beyond basic nutritional functions. Milk is more than a source of nutrients for any neonate of mammalian species, as well as for growth of children and nourishment of adult humans. Milk contains high components that provide the nutritive elements, immunological protection and biologically active substances as well as providing all the nutritional values for human and animals. Milk contains a wide range of a biologically active proteins such as casein and whey proteins have been found to be increasingly important for physiological and biochemical functions

that have crucial impacts on human metabolism and health [1-3]. Oral consumption of probiotics (live microbial feed supplement that enhance the host health by modulating the intestinal microbial balance) has been associated with the prevention, alleviation or cure of diverse intestinal disorders such as lactose intolerance, viral and bacterial diseases [4].

Probiotic is a live microbial Fermented food depending on the highly selection of lactic acid bacteria such as *Lactobacillus spp.*, *Bifidobacterium spp.* and *Streptococcus spp.*, with defined gut survival properties and associated biological activities, which can be ingested in fermented milk products or as a supplement. It have additional positive influences on health besides their nutritive value, if they are eaten in sufficient amounts [5]. Probiotic may also have multi-beneficial effects for human health [5-7]. A prebiotic is defined as "a non-digestible food ingredient that beneficially affects the host by selectively stimulating the growth and/or activity of one or a limited number of

*Address correspondence to these authors at the Department of Animal Production and Breeding, College of Agriculture and Veterinary Medicine, Qassim University, P.O. Box 6622, Buraidah 51452, KSA; Tel: 966 557 840 301; E-mail: mmzeitoun@yahoo.com

bacteria in the colon [8]. The synbiotic produced from the combination of pro- and prebiotic foods. These synbiotic functional foods raised the public awareness about their effectiveness to prevent/cure several health problems [9].

Environmental pollution has been a great challenge, since it contains smokes and suspended particles. Arsenic is known to be essential for life in small amounts [10], but sufficiently high exposures to inorganic As in natural environments, such as water, sediment and soil have proved to be toxic for plants, animals and humans.

Arsenic exposure caused by groundwater used for drinking in different parts of the world [11-12] has emerged as an issue of great concern. However, arsenic ingestion might also occur through consumption of foods. High levels of As exposure are commonly observed among the persons residing around mining areas and smelters, and those working in the wood preservation and pesticide industries using copper-chrome-arsenate (CCA) chemicals and other arsenical preparations, primarily through the inhalation of As-rich aerosols. A limited amount of this As intake is, however metabolized by the liver to the less toxic methylated forms and excreted through urine. Studies in some of European countries have shown that the average estimate of Arsenic intake through food of plant origin ranged from 10–20 µg As/day [13]. These values are equivalent to only 10–12% of the estimated dietary intakes of Arsenic in these countries. Bioaccumulation of Arsenic in crops grown in areas with elevated atmospheric deposition, contaminated lands, and areas irrigated with contaminated groundwater has raised concern about As ingestion through diet [14-15].

Recently, an evidence has shown potential adverse effects of arsenates on the mammalian reproductive system. Chiou *et al.* concluded that arsenic trioxide (As₂O₃) caused damage to sperm mobility and viability and disturbed spermatogenesis *via* reducing gene expression of the key enzymes in testosterone synthesis [16]. Kumar *et al.* also, found that exposure to the arsenic caused a decrease in testosterone level and degeneration of spermatogonia, which finally leads to infertility in male mice [17]. Dandelion was selected as a hepatic detoxifying agent which was expected to coordinate the removal of the toxic effects of arsenic by the liver.

Therefore, the present study aimed at investigating effects of an aqueous extract of dandelion alone, a

probiotic fermented cow milk or their combination (i.e. synbiotic) for ameliorating the toxic effects of arsenate on the male rats reproductive hormone, testis integrity and blood metabolites, including antioxidant enzyme, glutathione-s-transferase.

2. MATERIAL AND METHODS

2.1. Milk, Bacterial Culture and Dandelion

Milk samples were obtained from healthy lactating cows located at the experimental station of Qassim University (Al-Qassim, central region of Saudi Arabia). Starter cultures of *Streptococcus thermophilus*, *Lactobacillus acidophilus* and *Bifidobacterium bifidum* were obtained from Chr. Hansen's Laboratory, Copenhagen Denmark. Dandelion (*Taraxacum officinalis*) is a common herbs grown in middle-east. Dried leaves and roots of dandelion were purchased from local market.

2.2. Preparation of Probiotic Fermented Milk

Preparation of probiotic fermented milk was carried out according the method described by Tamime and Robinson [18]. Briefly, fresh cow milk has been standardized to attain 12 % total solids, heated at 85°C for 15 min., cooled to 40°C, inoculated with probiotic bacteria (2%) and incubated at 40°C for 4-8 h. After coagulation, the curd was tested for pH, stirred in an electric blender and stored refrigerated (5°C). The fresh milk was analyzed according to the AOAC method [19]. The chemical analysis of milk was as follow; 2.90% fat, 8.66 % solids not fat, 3.24% protein, 4.73% lactose, 0.65% ash, 1.0261 kg/m³ density and - 0.408 °C freezing point.

2.3. Preparation of Aqueous Extract of Dandelion (*Taraxacum officinalis*)

Dried dandelion (*Taraxacum officinalis*) leaves and roots were purchased from local market. Aqueous extract of dandelion (*Taraxacum officinalis*) was applied using the method of Awadh *et al.* [20] and Melendez and Capriles [21]. Briefly, the plant material was pulverized in a grinder, sixty grams of the pulverized material have been dissolved and extracted with 1000 ml hot distilled water in an electric blender which left running for 15 min. Afterwards, the suspension was left at room temperature for an hour, then filtered twice, first through cheese-cloth (50% cotton/50% polyester) and then through filter paper (Whatman No.2). The clear aqueous extract was preserved in sterile dark bottles (500ml) at - 20°C until further used.

2.4. Preparation of Synbiotic Fermented Milk

Synbiotic syrup was prepared by combining an equal volume of probiotic fermented milk with an equal volume of aqueous extract of dandelion (1v:1v).

2.5. Animals

Fifty adult male Wistar albino rats (*Rattus norvegicus*, average weight 125±20g) were obtained from the experimental animal unit of the College of Pharmacy, King Saud University, Riyadh, Saudi Arabia. Animals were kept under standard conditions of temperature and humidity in a ventilated room throughout the experimental period. The rats were fed on standard pellets of concentrated diet containing 20% crude protein and 75% TDN. Clean drinking water was allowed as a free choice. Animal procedures were performed in accordance with the ethics committee of Qassim University and according to the Guide for the Care and Use of Laboratory Animals of the National Institute of Health.

2.6. Experimental Design

The experiment lasted 8 consecutive weeks. Fifty male rats were randomly allotted into 5 groups (10 rats/treatment) as following:

Group 1: Negative control (C-) animals received basal diet only with accessibility to drinking water.

Group 2: Positive control (C+) animals received the basal diet in addition to drinking water containing the designed dose of sodium arsenate (30mg/L drinking water).

Group 3: Probiotic (PRO) animals received basal diet in addition to fermented milk formula replacing drinking water and contained 30mg sodium arsenate/L.

Group 4: Prebiotic (PRE) animals received basal diet in addition to an aqueous extract of dandelion replacing drinking water and contained same level of sodium arsenate.

Group 5: Synbiotic (SYN) animals received basal diet in addition to a mixture of PRE and PRO (1v:1v) replacing drinking water and contained same level of sodium arsenate.

2.7. Animals Sacrificial, Blood Collection and Testicular Histopathology

After an overnight deprivation of feed, rats were weighed, anesthetized (1:2:3, ethanol: chloroform:

diethyl ether, respectively) [22] and then sacrificed. A blood sample from each rat was collected in a non-heparinized tube by retro-orbital puncture using blood capillary tubes just prior to sacrificing. Blood samples were cooled in refrigerator for 2 hours prior centrifugation (3000 rpm, 15 min/5°C), sera were harvested in labeled tubes and deep frozen (-20°C) until further analyzed for biochemical variables and testosterone.

Both testes were directly separated after sacrificing, washed in an ice-cold saline, weighed then each pair of testes were identified and stored in a fixative (Formalin, 10% V/V). Testicular samples were subjected to histopathological sectioning (6 µm thickness) using an anatomical microtome (MICROM, International, GmbH, Germany). Histopathological examinations in testes were determined according to the method of Humason [23]. Histopathological changes in the testes sections stained with haematoxylin and eosin were evaluated by light microscopy (Olympus, X 400).

2.8. Serum Metabolites Determination

Alanine aminotransaminase (ALT) and aspartate aminotransaminase (AST) activities were determined according to the method of Reitman and Frankel [24]. Urea was determined in serum according to the method of Tietz [25]. Creatinine was determined in serum according to the method of Bonsnes and Taussky [26]. Triglycerides were quantified in serum according to the method of Stein and Myers [27]. Glutathione-S-transferase (GST) activity was determined according to Habig *et al.* [28].

2.9. Testosterone Determination in Serum

Using an ELISA commercial kit (Human Gesellschaft fur Biochemica und DiagnosticambH, Germany) according to the method of Rassaie *et al.* [29]. The method used a 100 µl of either standards or samples to be pipette into the microliter ELISA plate. A 100µl of the testosterone-horse radish peroxidase as a tracer was pipetted in all wells for competition reaction. Plate was tightly covered by a sticking film and incubated for one hour at room temperature. Contents of the plate were decanted and plate wells were washed 3 times by 300 µl washing solution each. After each wash plate was flipped down onto a bundle of tissue paper, a 100 µl substrate was added to each well and incubated for 15 minutes at room temperature. Then the reaction was stopped by adding a 100 µl stop

reagent (4N HCl). The color changes from blue to yellow which is read at 450 nm in a microplate reader. All samples were assayed in one assay in duplicates. The intra-assay CV was 3.8%, and the precision was 0.1 ng T/ml.

2.10. Testicular Testosterone Determination

Five grams of testes were taken out and subjected to sonication (Q Sonica 700, USA) for two cycles of 1500 rpm/45 sec. Samples were reconstituted in 5 ml physiological saline solution and centrifuged (3000 rpm/15 min./5°C). Supernatant was aspirated in a clean labeled tube and a 100 µl was taken and applied in same ELISA procedure used for serum testosterone determination [29].

2.11. Data Statistical Analyses

Data of body weight, testicular weight, blood metabolites and testosterone were analyzed by the least square analysis of variances using SAS package [30]. Significant differences were considered at $P < 0.05$. Differences between treatments were achieved by the Duncan's Multiple Range Test [31].

3. RESULTS

3.1. Biochemical Analysis

As shown in Table 1, arsenic increased ($P < 0.01$) triglycerides in blood (247.25 mg/dl) as compared to its level in negative control animals (126.00 mg/dl), however co-administration of prebiotic, probiotic and synbiotic restored the triglyceride level to its normal value (158.75, 160.7 and 135.25, respectively). Likewise, serum AST activity (Table 2) increased ($P < 0.01$) in positive control (141.01 U/L) than in negative control (64.71U/L) rats. Co-administration of prebiotic, probiotic and synbiotic restored AST normal activity (65.01, 68.61 and 59.11 U/L, respectively).

Table 1: Triglycerides (TG) in Rat Serum following Treatment with Arsenic in Group Fed on Prebiotic, Probiotic and Synbiotic

TG mg/dL			
Treatment	Mean	SD	CV
Control negative	126 ^a	15.165	12.03
Control positive	247.25 ^b	40.07	16.20
Prebiotic	158.75 ^a	29.94	18.86
Probiotic	160.75 ^a	8.95	5.57
Synbiotic	135.25 ^a	16.58	12.25

^aSD = standard deviation; ^bCV = coefficient of variation.

Table 2: Aspartate Aminotransferase (AST) in Rat Serum following Treatment with Arsenic in Group Fed on Prebiotic, Probiotic and Synbiotic

AST U/L			
Treatment	Mean	SD	CV
Control negative	64.7 ^a	7.63	11.79
Control positive	141.0 ^b	12.96	9.19
Prebiotic	65.0 ^a	6.14	9.45
Probiotic	68.6 ^a	14.37	20.95
Synbiotic	59.1 ^a	9.09	15.39

^aSD = standard deviation; ^bCV = coefficient of variation.

Similar trend was found in serum ALT activity (Table 3) as in rats exposed to arsenic alone (C+) an increased ALT activity (203.15 U/L) was 2.5 folds that in negative control rats (83.03 U/L). Co-administration of prebiotic, probiotic and synbiotic resulted in values of 88.85, 82.52 and 78.65 U/L, respectively restoring the normal value.

Table 3: Alanine Aminotransferase (ALT) in Rat Serum following Treatment with Arsenic in Group Fed on Prebiotic, Probiotic and Synbiotic

ALT U/L			
Treatment	Mean	SD	CV
Control negative	83.03 ^a	12.42	14.96
Control positive	203.15 ^b	51.41	25.31
Prebiotic	88.85 ^a	18.13	20.41
Probiotic	82.52 ^a	9.58	11.61
Synbiotic	78.65 ^a	14.81	18.83

^aSD = standard deviation; ^bCV = coefficient of variation.

Table 4 shows the creatinine and urea in rat serum following treatment with arsenic in group fed on prebiotic, probiotic and synbiotic. Data exhibit that serum creatinine concentration in arsenic alone-exposed rats exceeded 2 folds (90.21 µmol/l) that in negative control animals (42.32 µmol/l). Also, co-administration of prebiotic, probiotic and synbiotic resulted in values of 52.46, 44.34 and 39.69 µmol/l, respectively which are not different ($P > 0.05$) than negative control value. The levels of urea (mmol/L) were higher ($P < 0.01$) in rats fed on probiotic and synbiotic compared with prebiotic, negative and positive control rats.

Contrary to what was found before, glutathione-s-transferase activity (Table 5) decreased ($P < 0.01$) in arsenic-exposed rats (C+, 8.69 %) compared with

Table 4: Creatinine and Urea n Rat Serum following Treatment with Arsenic in Group Fed on Prebiotic, Probiotic and Synbiotic

Treatment	Creatinine $\mu\text{mol/L}$			Urea mmol/L		
	Mean	SD	CV	Mean	SD	CV
Control negative	42.32 ^a	9.45	22.33	7.43 ^a	0.816	10.98
Control positive	90.21 ^b	23.63	26.20	8.25 ^a	1.02	12.29
Prebiotic	52.46 ^a	3.06	5.84	7.82 ^a	0.80	10.23
Probiotic	44.34 ^a	11.18	25.21	14.36 ^b	6.11	42.53
Synbiotic	39.60 ^a	7.21	18.22	10.5 ^b	4.34	41.23

^aSD = standard deviation; ^bCV = coefficient of variation.

Table 5: Glutathione-s-Transferease (GST) Activity in rat Serum following Treatment with Arsenic in Group Fed on Prebiotic, Probiotic and Synbiotic

Treatment	GST					
	Min	Max	Mean	SD	C.V.	Activity* %
Control negative	0.144	0.216	0.18	0.033	18.26	18.75 ^a
Control positive	0.055	0.124	0.08	0.027	32.14	8.69 ^b
Prebiotic	0.112	0.177	0.15	0.032	21.25	15.71 ^a
Probiotic	0.174	0.265	0.22	0.038	16.85	23.18 ^a
Synbiotic	0.202	0.260	0.23	0.027	11.5	24.13 ^a

^aSD= standard deviation; ^bCV = coefficient of variation; *Activity = A/9.6*1000.

control (18.75 %). However, GST activity increased in the rats receiving prebiotic, probiotic and synbiotic in addition to arsenic compared with positive control. The correspondent values for prebiotic, probiotic and synbiotic were 15.71, 23.18 and 24.13, respectively being not different than negative control group.

3.2. Histopathological Analysis

3.2.1 Control Animals

The testis of control rats revealed normal large numbers of seminiferous tubules (Photo 1) with an outer capsule of fibroblastic connective tissue surrounding each seminiferous tubule followed by a basal lamina. A lining of scattered columnar Sertoli cells was obvious. Also, a layer of epithelial cells touches the basement membrane, forming the spermatogonia that invades the seminiferous tubules. Some spermatocytes appear large in size having condensed nuclear chromatin to produce secondary spermatocytes. The spermatids are identical in appearance to the secondary spermatocytes but of reduced nuclear diameters, their nuclei and cytoplasm passed complex morphological modification. In the seminiferous tubule lumen, spermatozoa are found with normal convoluted tails. The intertubular spaces are filled with the interstitial tissues. This is formed of loose

connective tissue containing Leydig cells, blood vessels and fibroblasts. Leydig cells are almost polyhedral in shape and strongly eosinophilic in light microscopy.

3.2.2. Treated Animals

Examination of testicular sections of the rats exposed to arsenic alone (C+) showed dislocation of germinal cells, which lost their normal architecture (Photo 2), the lumen of seminiferous tubules is filled with cellular debris and slight congestion of blood vessels and thickening of the interstitial tissue are obvious (Photo 3).

In the animals given arsenic and coadministered with dandelion aqueous extract, testicular section exhibited that spermatogenic cells lost their normal architecture with vacuolations among them and increased Leydig cell size was also noticed (Photo 4).

In rats given probiotic with arsenic (PRO), testicular sections showed normal appearance of the seminiferous tubules accompanied with normal distribution of spermatogenic cells and interstitial cells approaching the appearances of the negative control testicles (Photo 5).

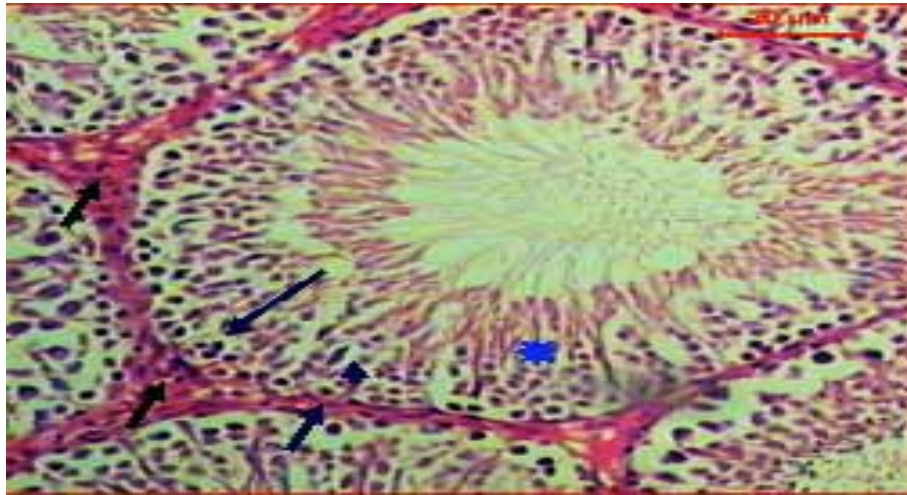


Photo 1: A micrograph section of the testis of a negative control (C-) rat showing intact seminiferous tubules, orderly arranged germ cells in the seminiferous tubules and strands of interstitial Leydig cells (green arrow). Notice: spermatogonia (arrow), spermatocytes (arrowhead), spermatids (asterisk) and interstitial connective tissue (short arrow) (H&E, Scale bar: 20 μm, X400).

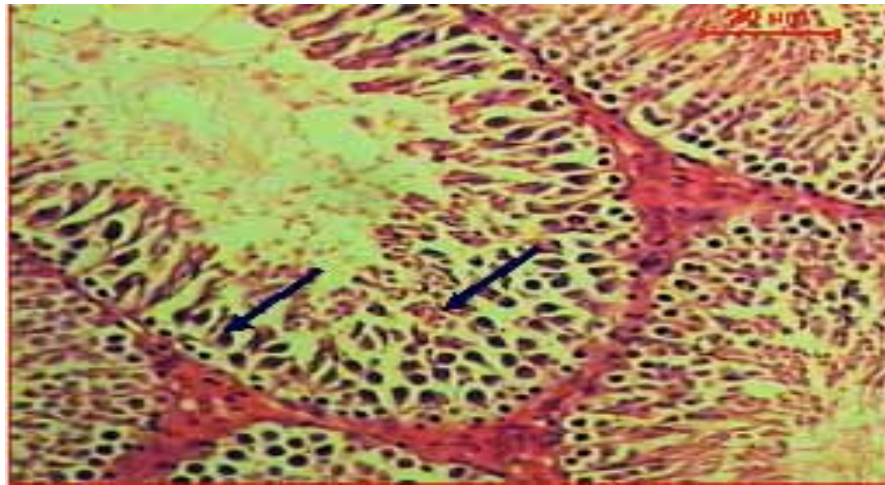


Photo 2: A micrograph section of the testis of a rat given arsenic alone (C+) showing dislocation of germinal cells, which lost their normal architecture (arrows) (H&E, Scale bar: 20 μm, X400).

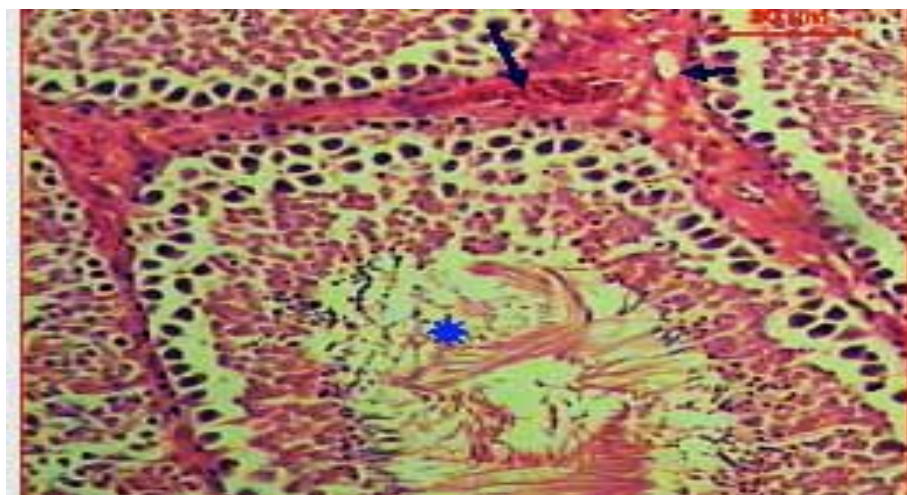


Photo 3: A micrograph section of the testis of a rat given arsenic alone (C+) showing the lumen of seminiferous tubules is filled with cellular debris (asterisk), slight congestion of blood vessels (arrow) and thickening of the interstitial tissue that associated with vacuoles (arrowhead) (H&E, Scale bar: 20 μm, X400).

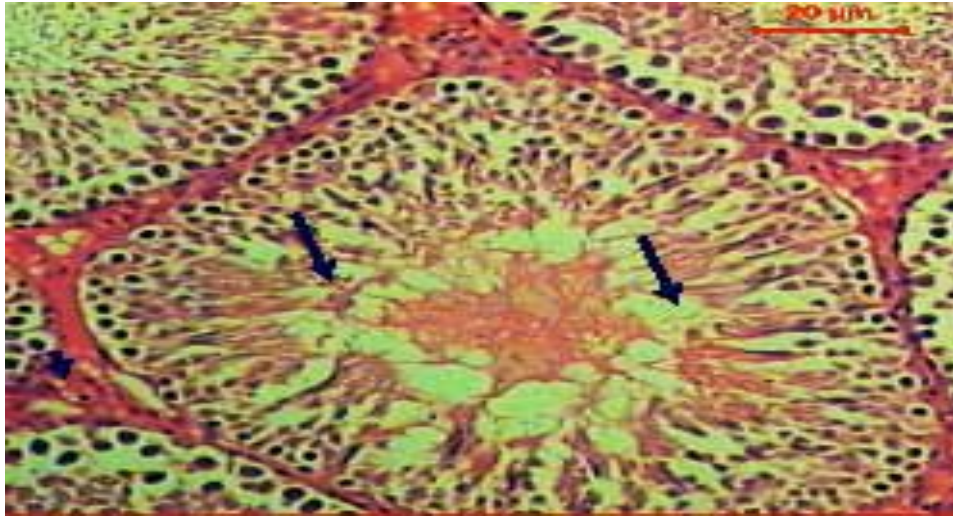


Photo 4: A micrograph section of the testis of a rat coadministered prebiotic (PRE) with arsenic showing spermatogenic cells losing their normal architecture with vacuulations among them (arrow) and Leydig cells increased in size (arrowhead) (H&E, Scale bar: 20 μ m, X400).

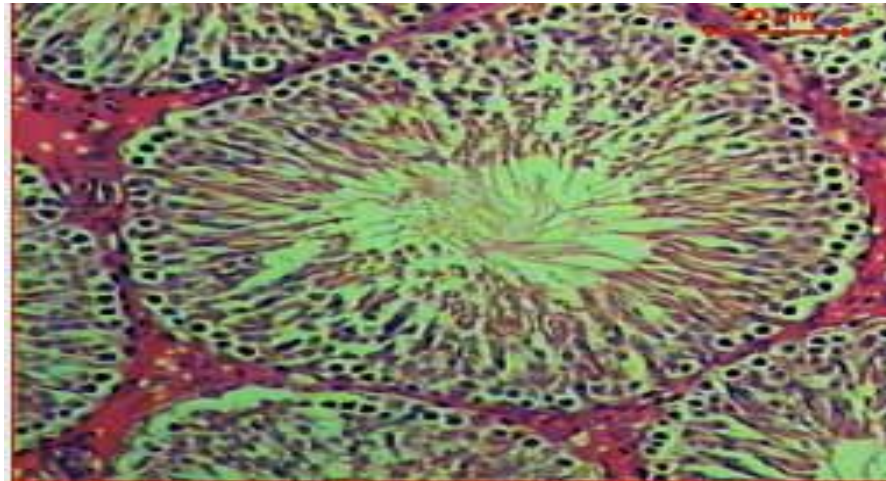


Photo 5: A micrograph section of the testis of a rat coadministered probiotic (PRO) and arsenic showing normal appearance (arrowheads) of seminiferous tubules architecture (H&E, Scale bar: 20 μ m, X400).

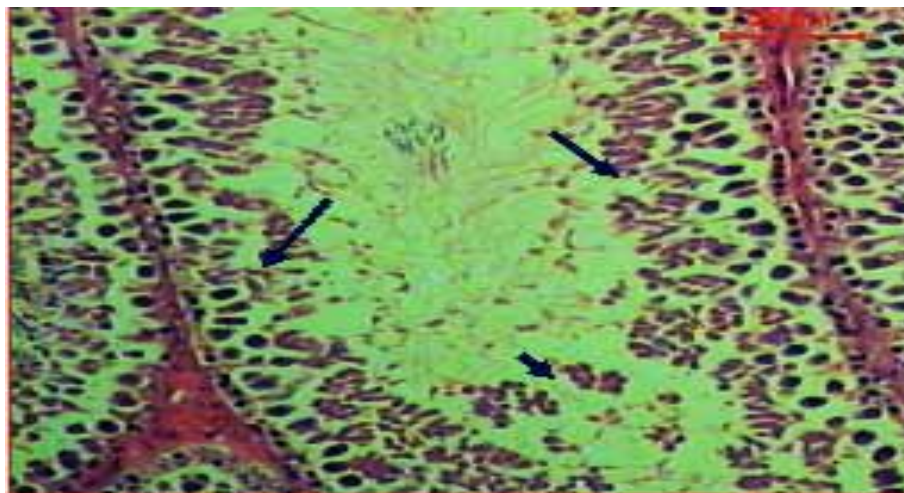


Photo 6: A micrograph section of the testis of a rat given synbiotic and arsenic (SYN) showing losing arrangement of spermatogenic cells and degeneration of some of them (arrow) and cell debris in the seminiferous tubule lumen (arrowhead) (H&E, Scale bar: 20 μ m, X400).

In rats given synbiotic with arsenic (SYN), the histopathological section reveals losing of the arrangement of spermatogenic cells and cell degeneration and cellular debris in its lumen (Photo 6).

3.3. Animals and Testes Weight

There were none significant differences ($P>0.05$) among treatments on animals body weight (Figure 1). Conversely, rats given arsenic (C+) exhibited heavier ($P<0.05$) testes (3.837 g) than these found in C- rats (3.492 g). Rats given probiotic (PRO) exhibited similar testes weight (3.499 g) as in the C- animals. On the other hand, PRE and SYN animals gave testes weights of 3.781 and 3.625 g, respectively which were similar to these in C+ animals (Figure 2).

3.4. Blood Testosterone

A significant ($P<0.01$) difference was found due to treatments on blood testosterone (T). Surprisingly, there found a negative synergistic effect between arsenic and dandelion extract on the blood testosterone level. The highest level of T was found in negative control (C-) animals (1.936 ng/ml), however the lowest T level was detected in PRE rats (1.198 ng/ml) followed by SYN rats (1.26 ng/ml). In PRO rats, testosterone levels was 1.517 ng/ml exhibiting an ameliorative effect (Figure 3).

3.5. Testicular Testosterone

Figure 4 depicts the levels of testicular tissues T. It has been found that arsenic significantly ($P<0.05$)

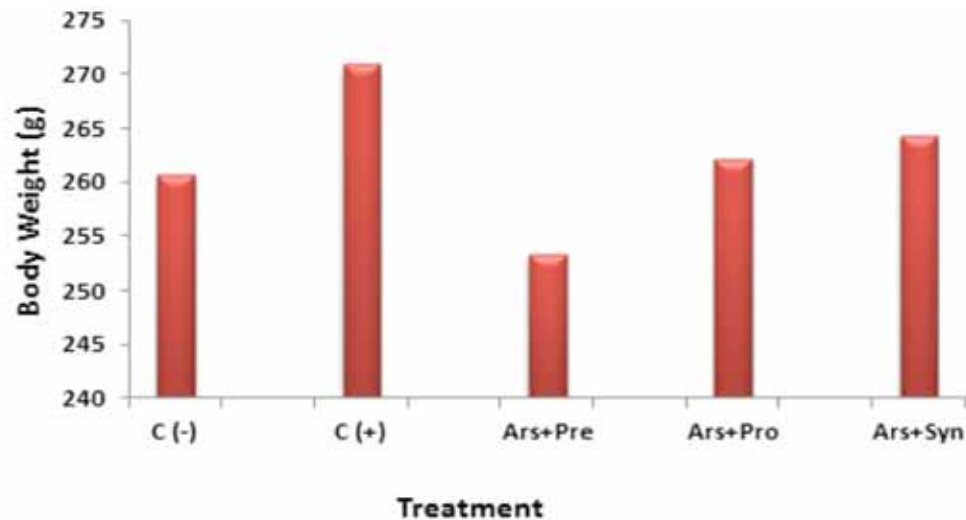


Figure 1: Rats body weight following treatment with arsenic in group fed on prebiotic, probiotic and synbiotic.

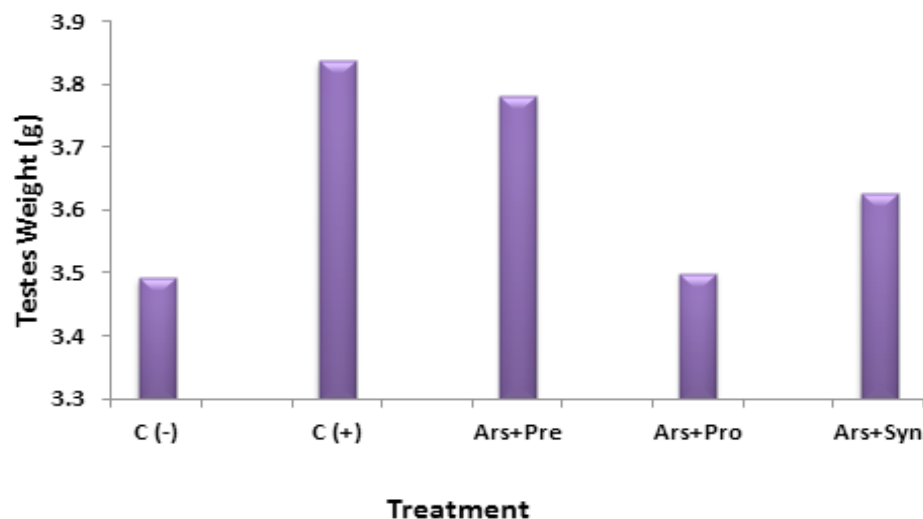


Figure 2: Rat testicular weight following treatment with arsenic in group fed on prebiotic, probiotic and synbiotic.

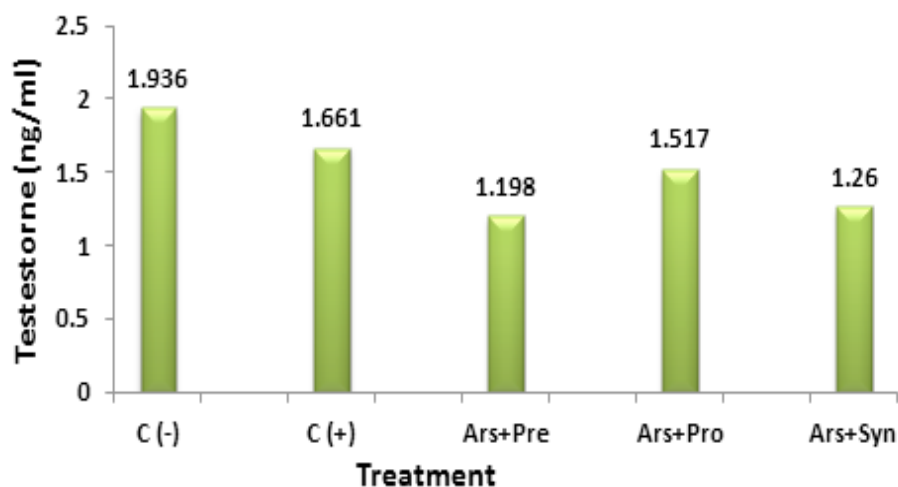


Figure 3: Rat serum testosterone levels in rat group following treatment with arsenic and fed on prebiotic, probiotic and synbiotic.

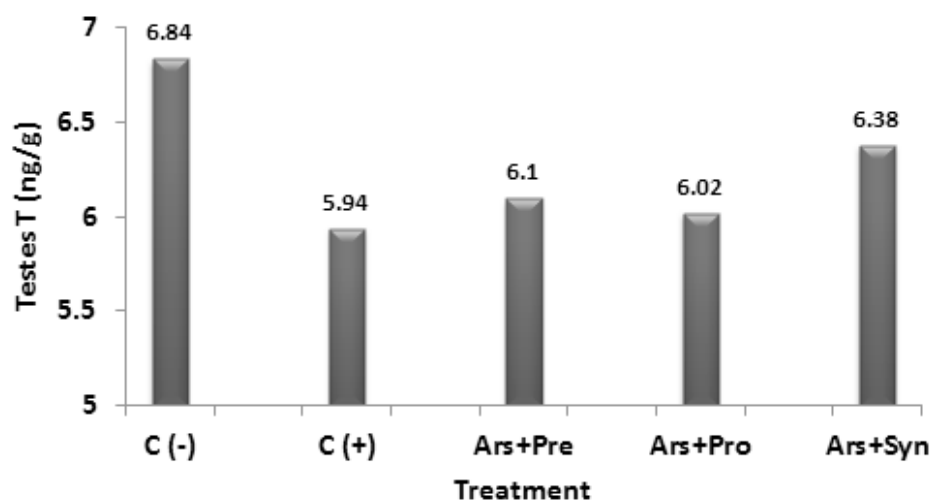


Figure 4: Rat testicular testosterone level in rat group following treatment with arsenic and fed on prebiotic, probiotic and synbiotic.

reduced T in the testicular tissues (5.94 ng/g). However, coadministration of the pre- (6.1 ng/g), pro- (6.02 ng/g) or synbiotic (6.38 ng/g) resulted in a shift towards the normal level of negative control (C-) animals.

It is noteworthy to compare the ratio of the blood T:Testes T in this study, as this might highlight the arsenic effects on the metabolism of the hormone. In negative control rats (C-) there found around 3.5 folds T in testes relative to that found in blood. Arsenic didn't change this ratio.

4. DISCUSSION

Toxicity with heavy metals has drawn the attention of several researchers around globe due to the heavy environmental pollution accompanying the industrial

revolution. Due to the existence of arsenic (As) in the surrounding area in plants, water, dust, soil, vapors and many others, males exposed to this metal have shown adverse effects in their semen characteristics [32]. Shen *et al.* stated that elevated urinary concentrations of As from general exposure to this metal are significantly associated with male infertility [33]. Also, As species may exert toxicity *via* oxidative stress and sexual hormone disrupting mechanisms as indicated by related biomarkers. Kumar *et al.* concluded that arsenic exposure caused a decrease in testosterone level and degeneration of spermatogonia, which finally leads to infertility in male mice [17]. The absolute decline in testosterone levels in both blood and testicular extract approached about 14% in the arsenic-intoxicated compared with negative control rats.

In PRO rats, testosterone levels was 1.517 ng/ml exhibiting an ameliorative effect (Figure 3) over that found in the rats given arsenic plus dandelion extract or these rats given arsenic plus a mixture of dandelion extract with probiotic fermented milk. There found significant increase in circulating testosterone when the probiotic fermented milk was given to the As-intoxicated rats, even though this level still below the normal (negative control) rats (1.936 ng/ml).

The significant increases in TG, ALT, AST and creatinine in C+ rats attributed to the arsenic were mentioned in rats [34], albino mice [35] and rabbits [36]. It is well known that liver is the main organ detoxifying the toxicants in the body. The increases in the releases of the hepatic enzymes into blood stream accompanying arsenic intoxication was explained by Karatas and Kalay [37] who attributed this adverse effect to the disintegrated hepatic cell organelles and membrane transports which leads to alteration in metabolic pathways.

Vutukuru *et al.* have also reported imbalances in hepatic enzyme activity in arsenic exposed *Labeorohita* [38]. Recently, Balasubramanian and Kumar found changes in hepatic enzymatic activity indicating damage to hepatic cells under intoxication of arsenic [39]. In the current study a parallel decrease in glutathione-s-transferase was observed in C+ rats, indicating that, not only the arsenic increased the hepatic cell leakage of AST and ALT but it also inhibited the releases of glutathione-s-transferase as an antioxidant enzyme, representing much oxidative stress on the organ. It is well known that arsenic toxicity causes oxidative stress and consequent reduction in the antioxidant enzymes, like glutathione-dependent enzymes which act positively against arsenic for self-cell defense [38]. Decreases in glutathione-s-transferase, glutathione peroxidase, glutathione reductase and catalase were observed by Allen and Rana [40] in arsenic-exposed liver and kidney. This can be correlated with changed activity of AST and ALT in animals exposed to arsenic.

The increased blood urea in male rats group treated with arsenic and fed on pro- and synbiotic diet are in agreement with the results obtained by Rana *et al.* [41]. The means values of serum urea were increased with increasing the level of protein in the diet and serum urea nitrogen is substance that is formed in the liver when the body breaks down protein. Probiotic and synbiotic diet are rich in micronutrients and protein. Also, elevated blood urea is known to be a function of

or related to increased protein catabolism in mammals and/or the conversion of ammonia to urea as a result of increased synthesis of arginase enzyme involved in urea production [42].

Saxena *et al.* reported significant increases in serum creatinine and urea in arsenic exposed albino rats [43]. Nephrotoxicity was assessed by estimating the serum levels of urea, uric acid and creatinine, the markers of renal dysfunction. Arsenic trioxide intoxication significantly increased the serum level of urea, uric acid and creatinine in comparison to control due to renal dysfunction [39]. Patel and Kalia reported increased blood urea and creatinine in experimental diabetic rats after sub-chronic exposure to arsenic [44]. Renal function impairment might result from intrinsic renal lesions, decreased perfusion of the kidney or due to deranged metabolic process caused by metal toxicity [45]. Exposure to arsenic or its various forms can lead to the nephrotoxicity in the experimental animals [46].

Arsenic exposure significantly ($p < 0.01$) reduced the testicular 3β -HSD and 17β -HSD activities, the testicular enzymes in charge of steroidogenesis, compared to the control rats [47]. Same authors also found a significant increase ($p < 0.05$) in cells with reactive oxygen species (ROS) generation following exposure to As when compared to control. The increase in testicular weight in the present study might be ascribed to the water retention accompanying As exposure. It is also known that arsenic trioxide administration results in the development of fluid retention [48-49].

Yang *et al.* [50] reported elevated levels of testosterone in mice co-administered with probiotic lactic acid bacteria and cyclophosphamide. Earlier studies have shown that lactic acid bacteria owe the ability to scavenge ROS and increase plasma antioxidant levels or protect plasma lipids from oxidation to different degrees [51]. Moreover, lactic acid bacteria were shown to prolong resistance of the lipoprotein fractions to oxidation, lower peroxidized lipoproteins and enhance total anti-oxidative activity [52]. The proposed mechanisms of probiotic-antioxidant activity involve the chelating ability of metal ions, ROS scavenging and reduced activity of intracellular cell-free extracts of lactic acid bacteria [52].

Recently, it has been found that dandelion aqueous extract was detrimental on the rats [53] and rams [54] testicles. The lower testosterone concentration observed in the dandelion-arsenic than in arsenic only-rats was attributed to the negative augmenting effect of dandelion on the Leydig cells which destabilizes the

cellular membranes resulting in more inhibition for the enzymes involved in testosterone biosynthesis [54]. Despite the hepatogenic activity of dandelion, it appears to exert some types of damage onto the spermatogenic cells through its alkaloids. The sesquiterpene lactones in dandelion, to some extent, have chemical steroidal structures similar to testosterone, mimicking its effect on the interstitial cells resulting in destabilization in the cellular membranes [54].

5. CONCLUSION

In conclusion, in arsenic intoxicated rats it is worthwhile to administer probiotic fermented milk enriched with lactic acid bacteria which would enhance the detrimental effects due to the arsenic exposure. However, giving dandelion (*Taraxacum officinale*) alone as a prebiotic or its co-administration with probiotic fermented milk (synbiotic) didn't totally cure the adverse effects of arsenic on male reproductive performance.

ACKNOWLEDGEMENTS

The authors acknowledge the funding from SABEC supporting the research project No. SR-S-1052 Qassim University, without which this work wouldn't have appeared.

CONFLICT OF INTEREST

Authors declare no conflict of interest exists.

REFERENCES

- [1] Clare DA, Swaisgood HE. Bioactive Milk Peptides: A Prospectus. *J Dairy Sci* 2000; 83: 1187-1195. [http://dx.doi.org/10.3168/jds.S0022-0302\(00\)74983-6](http://dx.doi.org/10.3168/jds.S0022-0302(00)74983-6)
- [2] Korhonen H, Pihlanto-Leppälä A. Milk-derived bioactive peptides: Formation and prospects for health promotion. In: *Handbook of Functional Dairy Products*, C. Shortt and J. O'Brien (eds). CRC Press, Boca Raton, FL. 2004; pp. 109-124.
- [3] Gobetti M, Minervini F, Rizzello CG. Bioactive peptides in dairy products. In: *Handbook of Food Products Manufacturing*, Y.H. Hui (ed). John Wiley & Sons, Inc., Hoboken, NJ. 2007; pp. 489-517. <http://dx.doi.org/10.1002/9780470113554.ch70>
- [4] McNaught CE, MacFie J. Probiotics in clinical practice: a critical review of the evidence. *Nutr Res* 2001; 21: 343-353. [http://dx.doi.org/10.1016/S0271-5317\(00\)00286-4](http://dx.doi.org/10.1016/S0271-5317(00)00286-4)
- [5] Salminen S, Bouley C, Boutron-Ruault M-C, Cummings JH, Franck A, Gibson GR, Isolauri E, Moreau M-C, Roberfroid M, Rowland I. Functional food science and gastrointestinal physiology and function. *Br J Nutr* 1998; 80: 147-171. <http://dx.doi.org/10.1079/BJN19980108>
- [6] Fuller R. History and development of probiotics. In *Probiotics. The Scientific Basis*, (Fuller, R., editor), Chapman & Hall Publishers (London) 1992.
- [7] Fuller R. Probiotics for Farm Animals. In: *Probiotics: A Critical Review*, Tannock, G.W. (Ed.). Horizon Scientific Press, New York, 1999; pp. 15-22.
- [8] Gibson GR, Roberfroid MB. Dietary modulation of the human colonic microflora: introducing the concept of prebiotics. *J Nutr* 1995; 125: 1401-1412.
- [9] McIntosh GH. Probiotics and colon cancer prevention. *Asia Pac J Clin Nutr* 1996; 5: 48-52.
- [10] Juillot F, Ildefonse PH, Morin G, Calas G, de Kersabiec AM, Benedetti M. Remobilization of arsenic from buried wastes at an industrial site: mineralogical and geochemical control. *Appl Geochem* 1999; 14: 1031-1048. [http://dx.doi.org/10.1016/S0883-2927\(99\)00009-8](http://dx.doi.org/10.1016/S0883-2927(99)00009-8)
- [11] Nriagu J. Arsenic in the Environment. Part II. Human Health and Ecosystem Effects. (Eds), New York, Wiley, 1994; pp. 293.
- [12] Bhattacharya P, Chatterjee D, Jacks G. Occurrence of arsenic-contaminated groundwater in alluvial aquifers from delta plains, eastern India: Options for safe drinking water supply. *Int J Water Resour Dev* 1997; 13: 79-92. <http://dx.doi.org/10.1080/07900629749944>
- [13] Weigert P, Muller J, Klein H, Zufelde KP, Hillebrand J, Arsen B. Cadmium und Quecksilber in und auf Lebensmitteln. Berlin: ZEB S Hefte 1 (in German). 1984; BGA, Berlin.
- [14] Xie ZM, Huang CY. Control of arsenic toxicity in rice plants grown on an arsenic-polluted paddy soil. Abstracts. 2nd Int. Conf. on Contaminants in the Soil Environment in the Australasia-Pacific Region, 1999; pp. 408. New Delhi, India.
- [15] Naidu R. Arsenic contamination of rural groundwater supplies in Bangladesh, India and Australia: implications for soil quality, animal and human health. In: P Bhattacharya, AH Welch, eds. *Arsenic in Groundwater of Sedimentary Aquifers*. Pre-Congress Workshop, 31st Int. 2000; 72-74. Geol. Cong., Rio de Janeiro, Brazil.
- [16] Chiou TJ, Chu ST, Tzeng WF, Huang YC, Liao CJ. Arsenic trioxide impairs spermatogenesis via reducing gene expression levels in testosterone synthesis pathway. *Chem Res Toxicol* 2008; 21: 1562-1569. <http://dx.doi.org/10.1021/tx700366x>
- [17] Kumar R, Khan SA, Dubey P, Nath A, Singh JK, Ali MD, Arun Kumar A. Effect of arsenic exposure on testosterone level and spermatogonia of mice. *WJPR* 2013; 2: 1524-1533.
- [18] Tamime AY, Robinson RK. *Yoghurt: Science and Technology*. Cambridge, (eds) UK: Wood head Publishers 1999.
- [19] AOAC. Official Method of Analysis of Association of Official Analytical chemist, Kenneth Helrich 15th Eds. Association of Official Analytical Chemists. Arlington, Virginia, 22201 USA 1990.
- [20] Awadh NA, Ali WD, Julich C, Kusnick U, Lindequist C. Screening of Yemeni medicinal plants for antibacterial and cytotoxic activities. *J Ethnophar* 2001; 74: 173-179. [http://dx.doi.org/10.1016/S0378-8741\(00\)00364-0](http://dx.doi.org/10.1016/S0378-8741(00)00364-0)
- [21] Melendez PA, Capriles VA. Antibacterial properties of tropical plants from Puerto Rico. *Phytomedicine* 2006; 13: 272-276. <http://dx.doi.org/10.1016/j.phymed.2004.11.009>
- [22] Wawersik J. History of Anesthesia in Germany. *J Clin Anesth* 1991; 3: 235-244. [http://dx.doi.org/10.1016/0952-8180\(91\)90167-L](http://dx.doi.org/10.1016/0952-8180(91)90167-L)
- [23] Humason GL, *Animal Tissue Techniques*. Fourth edition. W. H. Freeman and Company, San Francisco, USA 1979.
- [24] Reitman S, Frankel S. A colorimetric method for determination of serum glutamic oxaloacetic transaminase and glutamic pyruvic transaminase. *Am J Clin Path* 1957; 28: 56-63.
- [25] Tietz NW. *Fundamental of Clinical Chemistry*. (eds) W.B. Sanders & Co. Philadelphia, USA 1970; pp. 718.

- [26] Bonsnes RW, Taussky HH. Determination of creatinine in plasma and urine. *J Biochem* 1945; 58: 581-591.
- [27] Stein EA, Myers GL. National Cholesterol Education Program Recommendations for Triglyceride Measurement: Executive summary. *Clin Chem* 1995; 41: 1321-1426.
- [28] Habig MJ, Pabst WH, Jakoby WB. Glutathione S-transferases. The first enzymatic step in mercapturic acid formation. *J Biol Chem* 1974; 249: 7130-7139.
- [29] Rassaie MJ, Kumari GL, Pandey PK, Gupta N, Kochupilai PK, Grover N. A highly specific heterologous enzyme linked immunosorbent assay for measuring testosterone in plasma using antibody-coated immunoassay plates or polypropylene tubes. *Steroids* 1992; 57: 288-294. [http://dx.doi.org/10.1016/0039-128X\(92\)90062-E](http://dx.doi.org/10.1016/0039-128X(92)90062-E)
- [30] SAS, Statistical Analysis System User's Guide (Version 8). SAS Institute Inc, Cary NC, USA 2000.
- [31] Steel RGD, Torrie JH. Principles and Procedures of Statistics. McGraw-Hill Book Company Inc., NY, USA 1980.
- [32] Sengupta M, Deb I, Sharma GD, Kar KK. Human sperm and other seminal constituents in male infertile patients from arsenic and cadmium rich areas of Southern Assam. *SBIRM*, 2013; 59: 199-209.
- [33] Shen H, Xu W, Zhang J, Chen M, Martin F, Xia Y, Liu L, Dong S, Zhu YG. Urinary Metabolic Biomarkers Link Oxidative Stress Indicators Associated with General Arsenic Exposure to Male Infertility In a Han Chinese Population. *Environ Sci Technol* 2013; 47: 8843-8851.
- [34] Islam MN, Awal MA, Rahman MM, Islam MS, Mostofa M. Effects of arsenic alone and in combination with selenium, iron and zinc on clinical signs, body weight and hematobiochemical parameters in long evans rats. *Bang J Vet Med* 2005; 3: 75-77.
- [35] Sharma A, Sharma MK, Kumar M. Protective effect of Mentha piperita against arsenic induced toxicity in liver of Swiss albino mice. *Basic Clin Pharmacol Toxicol* 2007; 100: 249-257. <http://dx.doi.org/10.1111/j.1742-7843.2006.00030.x>
- [36] Ahmed S. Effect of filtration of arsenic contaminated water and interaction of arsenic with few reagents in rabbit. MS Thesis, Dept. of Pharmacology, Bangladesh Agri. University, Bangladesh 2004.
- [37] Karatas S, Kalay M. Accumulation of lead in the gill, liver, kidney and brain tissues of Tilapia zilli. *Turk J Vet Anim Sci* 2002; 26: 471-477.
- [38] Vutukuru SS, Prabhath NA, Ragaverder M, Yeramilli A. Effect of arsenic and chromium on the serum aminotransferases activity in the Indian major carp, Labeo rohita. *Int J Environ Res Public Health* 2007; 4: 224-227. <http://dx.doi.org/10.3390/ijerph2007030005>
- [39] Balasubramanian J, Kumar A. Study of Arsenic Induced Alteration in Renal Function in Heteropneustes fossilis, and It's Chelation by Zeolite. *Adv Biores* 2013; 4: 8-13.
- [40] Allen T, Rana S. Effect of arsenic (AsIII) on glutathione-dependent enzymes in liver and kidney of the freshwater fish *Channapunctatus*. *Biol Trace Elem Res* 2004; 100: 39-48. <http://dx.doi.org/10.1385/BTER:100:1:039>
- [41] Rana SV, Rekha S, Seema V. Protective effects of few antioxidants on liver function in rats treated with cadmium and mercury. *Indian J Exp Biol* 1996; 34: 177-179.
- [42] Harper HA, Rodwell VW, Mayes PA. Review of Physiological Chemistry. Los Altos, CA USA: Lange Medical Publications 1979.
- [43] Saxena PN, Shalini A, Nishi S, Priya B. Effect of arsenic trioxide on renal functions and its modulation by Cucurmaromatica leaf extract in albino rat. *J Environ Biol* 2009; 30: 527-531.
- [44] Patel HV, Kalia K. Sub chronic arsenic exposure aggravates nephrotoxicity in experimental diabetic rats. *J Exp Biol* 2010; 48: 762-768.
- [45] Cameron JS, Greger R. Renal function and testing of function. (Davidson AM, Cameron JS, Grunfeld JP, Kerr DNS, Rits E, Winearl GC (Eds.) Oxford Textbook of Clinical Nephrology 1998; pp. 36-39.
- [46] Ayala-Fierro F, Baldwin AC, Wilson LM, Valeski JE, Carter DE. Structural alterations of rat kidney after acute arsenic exposure. *Lab Invest* 2007; 80: 87-97. <http://dx.doi.org/10.1038/labinvest.3780012>
- [47] Khan S, Telang AG, Malik JK. Arsenic-induced oxidative stress, apoptosis and alterations in testicular steroidogenesis and spermatogenesis in Westar rats: ameliorative effect of curcumin. *WJPP* 2013; 2: 33-48.
- [48] Camacho LH, Soignet SL, Chanel S, Ho R, Heller G, Scheinberg DA, Ellison R, Warrell RP. Leukocytosis and the retinoic acid syndrome in patients with acute promyelocytic leukemia treated with arsenic trioxide. *J Clin Oncol* 2000; 18: 2620-2625.
- [49] Soignet SL, Frankel SR, Douer D, Tallman MS, Kantarjian H, Calleja E, Stone RM, Kalaycio M, Scheinberg DA, Steinherz P, Sievers EL, Coutré S, Dahlberg S, Ellison R, Warrell RP. United States multicenter study of arsenic trioxide in relapsed acute promyelocytic leukemia. *J Clin Oncol* 2001; 19: 3852-3860.
- [50] Yang JL, Wen M, Pan KC, Shen KF, Yang R, Liu ZH. Protective effects of dietary co-administration of probiotic Lactobacillus caesi on CP-induced reproductive dysfunction in adult male Kummung mice. *Vet Res* 2012; 5: 110-119.
- [51] Kullisaar T, Songisepp E, Mikelsaar M, Zilmer K, Vihalemm T, Zilmer M. Antioxidative probiotic fermented goats milk decreases oxidative stress-mediated atherogenicity in human subjects. *Br J Nutr* 2003; 2: 449-456. <http://dx.doi.org/10.1079/BJN2003896>
- [52] Lin MY, Yen CL. Antioxidative ability of lactic acid bacteria. *Agric Food Chem* 1999; 4: 1460-1466.
- [53] Tahtamouni LH, Alqurna NM, Al-Hudhud MY, Al-Hajj HA. Dandelion (Taraxacum officinale) decreases male rat fertility *in vivo*. *Journal of Ethno-Pharmacol* 2011; 26: 102-109. <http://dx.doi.org/10.1016/j.jep.2011.02.027>
- [54] Zeitoun MM, Farahna M, Al-Sobayil KA, Abdel-Salam AM. Impact of the aqueous extract of dandelion, probiotic and their synbiotic on male lamb's testicular histopathology relative to semen characteristics. *OJAS* 2014; 4: 23-30. <http://dx.doi.org/10.4236/ojas.2014.41004>

Received on 03-10-2014

Accepted on 14-10-2014

Published on 12-11-2014

<http://dx.doi.org/10.6000/1927-5129.2014.10.65>© 2014 Al-Damegh *et al.*; Licensee Lifescience Global.

This is an open access article licensed under the terms of the Creative Commons Attribution Non-Commercial License (<http://creativecommons.org/licenses/by-nc/3.0/>) which permits unrestricted, non-commercial use, distribution and reproduction in any medium, provided the work is properly cited.