

Gastrografin Enemas for Treatment of Distal Intestinal Obstruction Syndrome in Children and Adults with Cystic Fibrosis

Mahmoud Zahra¹, Carla Frederick², Richard Thomas¹, Vaseem Iqbal¹ and Drucy Borowitz^{3,*}

¹Department of Radiology, Women and Children's Hospital of Buffalo, 219 Bryant Street, Buffalo, NY, 14222, USA

²Department of Medicine, State University of New York at Buffalo, Women and Children's Hospital of Buffalo, 219 Bryant Street, Buffalo, NY, 14222, USA

³Department of Pediatrics, State University of New York at Buffalo, Women and Children's Hospital of Buffalo, 219 Bryant Street, Buffalo, NY, 14222, USA

Abstract: *Background:* Distal intestinal obstruction syndrome (DIOS) presents in both children and adults with cystic fibrosis (CF). When DIOS is characterized by bilious vomiting or when washout therapy with polyethylene glycol has failed, radio-opaque hypertonic enema (ROHE) is recommended as the next therapeutic option. Techniques for use of ROHE in infants with meconium ileus are described in the literature but have not been reported for children and adults with DIOS.

Methods: We described the technique, volume, and results of Gastrografin enema usage for DIOS in children and adults with CF at our institution between 2006 and 2011. We reviewed the incidence of DIOS reported to the CF Foundation Patient Registry (CFFPR) between 2001 and 2011

Results: The mean amount of dilute Gastrografin used was 1220ml or 31 ml/kg, (range 240 - 3500ml; 19 – 59 ml/kg). Three patients had incomplete resolution after an initial enema and underwent repeat enemas on consecutive days. The incidence of DIOS in the CFFPR increased from 223 to 498 cases in children <18 years and 380 to 813 cases in adults >18 years over the ten year period studied.

Conclusions: Large volume radio-opaque hypertonic enemas can resolve episodes of acute DIOS and can be repeated on subsequent days if needed, without complications. The incidence of DIOS reported to the United States CF Foundation Patient Registry has increased in both children and adults over the past decade.

Keywords: Therapeutic intervention, radio-opaque hypertonic enema, DIOS.

BACKGROUND

Pulmonary manifestations are the leading causes of morbidity and mortality in patients with cystic fibrosis (CF). Abnormal viscid secretions cause airway obstruction and infection. Recurrent infection and longstanding obstruction result in bronchitis and bronchiectasis, and pulmonary complications are the primary reason that CF is a life-shortening disease. However, gastrointestinal manifestations are seen in the majority of patients and can cause significant morbidity. Gastrointestinal manifestations include meconium ileus, pancreatic insufficiency, distal intestinal obstruction syndrome (DIOS), malabsorption, gallbladder sludge or cholelithiasis and liver disease [1].

Distal intestinal obstruction syndrome presents in both children and adults with CF. Several risk factors have been identified. These include severe genotype,

pancreatic insufficiency, poorly controlled fat malabsorption, dehydration, history of meconium ileus, history of DIOS, organ transplantation, and CF related diabetes [2].

DIOS occurs in children ranging from 5 to 12 episodes per 1000 patients per year [3] and with a higher prevalence in adults [4]. Clinically, DIOS may mimic acute appendicitis or partial/complete bowel obstruction. It manifests by colicky abdominal pain, constipation, distended abdomen and vomiting. Physical examination may demonstrate a mass in the right lower abdomen due to impacted stool. Abdominal radiograph findings may show varying degrees of localized or diffuse distension of small bowel loops with or without fluid levels, and a large burden of stool at the ileocecal junction. Clinical scenario and plain radiography are sufficient to make the diagnosis of DIOS in most situations.

Acute episodes of DIOS are traditionally managed in a stepwise approach as there is no standardized therapy proven by randomized clinical trials. In the case of DIOS with partial obstruction, resolution often

*Address correspondence to this author at the Department of Pediatrics, Women and Children's Hospital of Buffalo, 219 Bryant Street, Buffalo, NY 14222, USA; Tel: 716-878-7524; Fax: 716-888-3945; E-mail: dborowitz@upa.chob.edu

can be achieved with hydration, stool softeners, and administration of polyethylene glycol orally, by nasogastric tube, or if present, by gastrostomy tube [2]. However, when DIOS is characterized by bilious emesis or when washout therapy with polyethylene glycol has failed, radio-opaque hypertonic enema (ROHE) is the next therapeutic option. Despite this common treatment strategy there is scant mention in the literature of the specific method to provide ROHE for DIOS. Treatment of neonatal meconium ileus by Gastrografin enema has been described noting similar dilution as the manufactures label but smaller volumes [5]. The goal of this case series is to describe the technique for delivery of ROHE using Gastrografin (sodium diatrizoate and meglumine diatrizoate) in children and adults with DIOS.

METHODS

Records of patients with CF followed at the Cystic Fibrosis Center of Western New York at the Women and Children's Hospital of Buffalo who were treated for DIOS with Gastrografin enemas between 2006 and 2011 were reviewed retrospectively. This study was approved by the Children and Youth Institutional Review Board of the State University of New York at Buffalo. We recorded the age and weight of the patient at the time of enema, gender, volume of Gastrografin used, whether there were signs of small intestinal obstruction, how much stool was present, how far into the bowel the enema was refluxed, and whether there were any complications to the procedure such as bowel perforation, patient dehydration or electrolyte imbalance.

All patients were admitted to the hospital and given intravenous hydration. Abdominal radiograph and/or CT scan with oral and intravenous contrast were performed before the enemas. The radiologic studies were reviewed by attending radiologists; the diagnosis of distal intestinal obstruction was confirmed clinically and radiologically. If air-fluid levels were seen or if patients failed oral lavage with polyethylene glycol, we proceeded to ROHE with Gastrografin.

The Gastrografin enema technique is as follows:

- The procedure is performed only as an inpatient procedure; the patient is given intravenous fluids before and after the enema to prevent potential complications due to Gastrografin-induced fluid shifts.
- There is no standard quantity of diluted Gastrografin solution used. The objective is to fill

the colon and attempt to reflux the contrast into the distal small bowel. Most patients need 20-50 ml/kg. Gastrografin is available as a concentration of 660 mg/ml diatrizoate meglumine, 100 mg/ml diatrizoate sodium and 367 mg/ml organically bound iodine in vials containing 240ml which are diluted with tap water (1:4). A solution of 500 - 1000ml is prepared and 500ml aliquots are added as needed.

- A lubricant is used and the enema tube tip is carefully inserted; the catheter balloon is not inflated. The tube is secured in place with tape.
- The contrast enema is typically initiated with the patient in left lateral position for better evaluation of the rectum.
- Once in place, the enema tube is unclamped and Gastrografin is introduced into the colon under hydrostatic pressure and fluoroscopic monitoring.
- If injection by syringe is needed due to cessation of Gastrografin passage, contrast is injected slowly under fluoroscopic monitoring.
- Representative images on the fluoroscopic monitor can be archived as documentation. The point of proximal reflux of contrast is documented
- Enemas are repeated if indicated clinically. Repeat enemas are delayed until 16-24 hours after the first attempt to allow enough time for the Gastrografin effect to take place.

In addition to the retrospective chart review, we examined the Cystic Fibrosis Foundation's Patient Registry over the past 10 years to assess the occurrence of DIOS by age less than or greater than 18 years. Accredited CF Centers contribute information about the incidence of complications such as DIOS to this registry and annual reports are distributed to CF Center Directors.

RESULTS

Between 2006 and 2012, 12 Gastrografin enemas were performed on 8 unique inpatients with CF and acute DIOS with bilious vomiting or for whom washout therapy with polyethylene glycol failed (2 female and 6 male). The mean age was 22.25 years, (range 2-49 years).

The volume of diluted Gastrografin used was unavailable for 4 enemas; the mean amount used in 8 separate enemas was 1220ml or 31 ml/kg, (range 240 - 3500ml; 19 – 59 ml/kg). Three patients had incomplete resolution after an initial enema. Two of these underwent repeat enema the following day; one patient underwent three enemas on three consecutive days. Repeat enemas were needed in these patients despite reflux of Gastrografin into the terminal ileum. One patient developed a second episode of acute DIOS that required treatment with a Gastrografin enema 6 months after an initial treatment. All patients were treated without any complications and were discharged after resolution of DIOS (Table 1).

The number of patients followed in the Registry increased between 2001 and 2011 from 22,732 to 27,111. The relative incidence of DIOS reported to the

US CF Foundation Patient Registry increased in this same ten-year period from 2.9% to 3.8% in children and from 2.9% to 5.8% in adults. Thus, the absolute incidence increased, from 223 to 498 cases in children under age 18 years and 380 to 813 cases in adult over age 18 years (Figure 1).

CONCLUSIONS

Advances in research have led to treatments to improve lung disease in CF but the burden of extra-pulmonary disease and GI symptoms is increasing due to this extended lifespan. DIOS is now seen more frequently than before. Treatment of DIOS has not been the subject of randomized controlled trials. Although use of ROHE for treatment of refractory DIOS has been advocated, no in-depth description of the technique has been published outside of the neonatal

Table 1: Patients Treated with Gastrografin Enemas for Acute DIOS

Patients	Age at the time of enema (gender)	Weight (kg)	Volume of Gastrografin in ml (ml/kg)	Evidence of small bowel obstruction	Amount of stool	Contrast flowed to	Comments
Patient 1	21Y (M)	59kg	3500ml (59 ml/kg)	+	Moderate	Ascending colon	No complication
Patient 2a	16Y (M)	68kg	1900ml (28 ml/kg)	+	Moderate	Terminal ileum	No complication obstruction not resolved
Patient 2b	16Y (M)	68kg	2160ml (32 ml/kg)	+	Moderate	Cecum	No complication
Patient 3	9Y (M)	42kg	1200ml (29 ml/kg)	-	Moderate	Ascending colon	No complication
Patient 3*	10Y (M)	42kg	1200ml (29 ml/kg)	-	Moderate	Terminal ileum	No complication
Patient 4	49 (M)	N/A	Information not available	-	Moderate	Cecum	No complication
Patient 5	7Y (F)	26kg	750ml (29 ml/kg)	-	Moderate	Terminal ileum	No complication
Patient 6a	34Y (M)	79kg	Information not available	+	Large	Terminal ileum	No complication obstruction not resolved
Patient 6b	34Y (M)	79kg	Information not available	+	Moderate	Cecum	No complication obstruction not resolved
Patient 6c	34Y (M)	79kg	Information not available	+	Moderate	Terminal ileum	No complication
Patient 7	2y (F)	12.5Kg	240 ml (19 ml/kg)	+	Moderate	Cecum	No complication
Patient 8	30y (M)	84.6Kg	2500ml (29 ml/kg)	-	Mild	Terminal ileum	No complication

Numbers represent unique patients; letters indicate enemas given during the same admission; asterisk indicates a patient readmitted six months later for a separate episode of DIOS that required treatment.

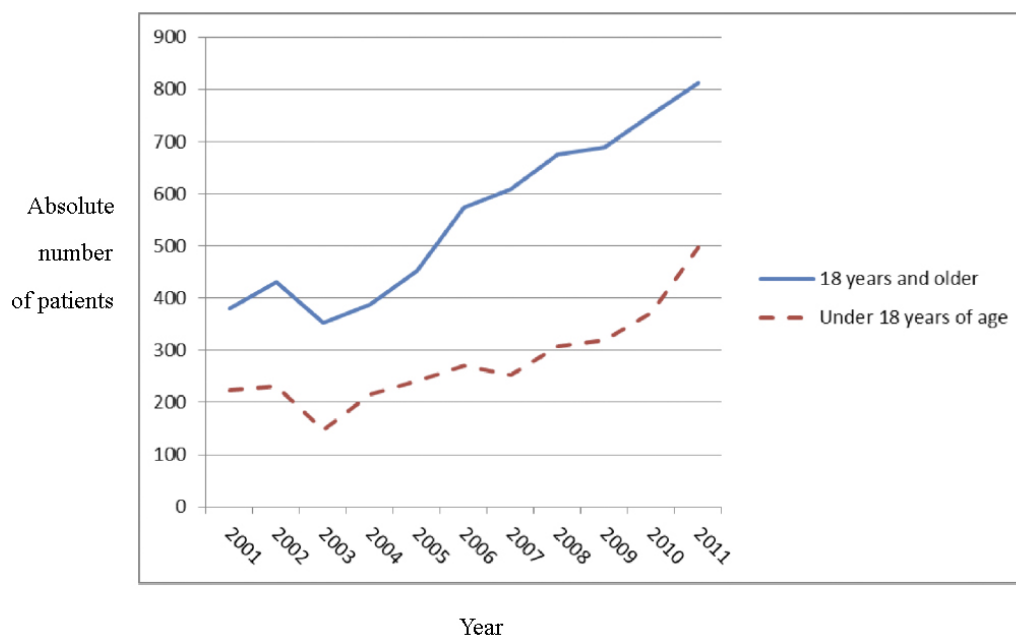


Figure 1: Incidence of DIOS as reported to the CF Foundation Patient Registry 2001-2011 by age category.

age range. In a case series describing oral Gastrografin lavage, the authors only provide a brief description of the technique used for Gastrografin enema if the oral lavage fails [6]. Use of ROHE for CF patients beyond the neonatal period is largely based on theory relative to what is known about the pathophysiology of DIOS. Given that the proximal point of obstruction or partial obstruction is frequently the distal ileum, use of dilute Gastrografin in large enough volumes to be able to reflux into the distal small bowel is standard practice. In some cases this is not possible secondary to inspissated stool in proximal colon. Hypertonic enemas are used to draw water into the bowel to loosen dessicated enteric contents. Care should be taken to hydrate the patient well before and after the enema because of potential complications due to Gastrografin-induced fluid shifts [7]. No episodes of bowel perforation, dehydration or electrolyte imbalance were seen in the patients described here.

In our case series, no radiologic signs were identified that predict the need for more than one Gastrografin enema. Success of the enema was not related to the most proximal point of Gastrografin reflux. Repeat enemas were needed even when Gastrografin was able to reach the terminal ileum and conversely, clinical resolution was seen when Gastrografin only reached to the ascending colon. Finally, the volume of Gastrografin needed was not related to any findings that were determined prior to the procedure. Factors that can help increase the efficacy and predict the success of the procedure may not be

able to be predicted given the diverse presentation of DIOS; however examination of larger numbers of cases may reveal trends that were unable to be discerned in this small case series. Clinicians should consider other diagnoses if DIOS does not resolve after repeated ROHE [1, 2]. The incidence of malignancies of the gastrointestinal tract is increasing in patients with CF [8] and this should be ruled out in any case of difficult-to-manage DIOS.

In our institution, Gastrografin has been used for ROHE. However, other agents may also be efficacious. It is unknown whether the degree of hyperosmolarity or the specific types of cations and anions in Gastrografin make it efficacious. In a study of magnetic resonance imaging oral agents, the physico-chemical properties of the agents were less important for bowel distention than osmolarity, presumably because the osmolarity drew fluid into the bowel to allow it to expand [9]. This report is limited by the number of subjects studied and the retrospective nature of our review. Prospective, randomized trials comparing different types of hyperosmotic enemas during episodes of DIOS would be difficult to implement. *Cftr* knockout mice develop DIOS upon weaning [10]. Although this type of bowel obstruction is not identical to DIOS it may provide an opportunity to bring a more scientific approach to treatment per rectum of this uncommon but urgent clinical problem.

We have demonstrated that, based on the US CF Patient Registry, the incidence of DIOS is increasing in

both children and adults with CF. Although most cases of DIOS will resolve with “simple laxatives” [11], ROHE may be needed in some instances. To aid CF clinicians and radiologists caring for patients with DIOS, we have described a technique and demonstrated that large volumes of Gastrografin can be delivered by enema and can be repeated on subsequent days if needed, without complications, and we remind clinicians to consider other causes of obstruction if repeated enemas do not relieve symptoms.

The authors have not identified any conflicts of interest. Dr. Borowitz is supported by grant BOROWI03CS0 awarded by Cystic Fibrosis Foundation Therapeutics, Inc.

REFERENCES

- [1] Gelfond D, Borowitz D. Gastrointestinal complications of cystic fibrosis. *Clin Gastroenterol Hepatol* 2013; 11: 333-42. <http://dx.doi.org/10.1016/j.cgh.2012.11.006>
- [2] Colombo C, Ellemunter H, Houwen R, *et al.* on behalf of the ESPGHAN Cystic Fibrosis Working Group. Guidelines for the diagnosis and management of distal intestinal obstruction syndrome in cystic fibrosis patients. *JCF* 2011; 10(Suppl 2): S24-S28
- [3] Houwen RH, van der Doef HP, Sermet I, *et al.* on behalf of the ESPGHAN Cystic Fibrosis Working Group. Defining DIOS and constipation in cystic fibrosis with a multicentre study on the incidence, characteristics, and treatment of DIOS. *J Pediatr Gastroenterol Nutr* 2010; 50: 38-42. <http://dx.doi.org/10.1097/MPG.0b013e3181a6e01d>
- [4] Andersen HO, Hjelt K, Waever E, Overgaard K. The age-related incidence of meconium ileus equivalent in a cystic fibrosis population: the impact of a high energy intake. *J Pediatr Gastroenterol Nutr* 1990; 11: 355-60.
- [5] Shinohara T, Tsuda M, Koyama N. Management of meconium-related ileus in very low-birth weight infants. *Pediatrics Int* 2007; 49: 641-44. <http://dx.doi.org/10.1111/j.1442-200X.2007.02457.x>
- [6] O'Halloran SM, Gilbert J, McKendrick OM, *et al.* Gastrografin in acute meconium ileus equivalent. *Arch Dis Child* 1986; 61: 1128-1110
- [7] Cappell MS. Colonic toxicity of administered drugs and chemicals. *Am J Gastroenterol* 2004; 99(6): 1175-90. <http://dx.doi.org/10.1111/j.1572-0241.2004.30192.x>
- [8] Maisonneuve P, Marshall BC, Knapp EA, Lowenfels AB. Cancer risk in cystic fibrosis: a 20-year nationwide study from the United States. *J Natl Cancer Inst* 2013; 105(2): 122-9. <http://dx.doi.org/10.1093/inci/djs481>
- [9] Borthne AS, Abdelnoor M, Storaas T, Pierre-Jerome C, Kløw NE. Osmolarity: a decisive parameter of bowel agents in intestinal magnetic resonance imaging. *Eur Radiol* 2006; 16(6): 1331-6. <http://dx.doi.org/10.1007/s00330-005-0063-7>
- [10] Cottart CH, Bonvin E, Rey C, Wendum D, Bernaudin JF, Dukont S, *et al.* Impact of nutrition of phenotype in Cfr-deficient mice. *Pediatr Res* 2007; 65(5): 528-32. <http://dx.doi.org/10.1203/PDR.0b013e318155a61d>
- [11] Subhi R, Ooi R, Kotsimbos T, Wilson J, Lee WR, Wale R, Warriar S. Distal intestinal obstruction syndrome in cystic fibrosis: presentation, outcome and management in a tertiary hospital (2007-2012). *ANZ J Surg* 2013. [Epub ahead of print]. <http://dx.doi.org/10.1111/ans.12397>

Received on 11-02-2014

Accepted on 11-04-2014

Published on 30-04-2014

DOI: <http://dx.doi.org/10.6000/1927-5951.2014.04.02.1>

© 2014 Zahra *et al.*; Licensee Lifescience Global.

This is an open access article licensed under the terms of the Creative Commons Attribution Non-Commercial License (<http://creativecommons.org/licenses/by-nc/3.0/>) which permits unrestricted, non-commercial use, distribution and reproduction in any medium, provided the work is properly cited.