




Published by SET Publisher

Journal of Pharmacy and Nutrition Sciences

ISSN (online): 1927-5951



## Gum Arabic and Eugenol in a Silica-Induced Inflammatory Angiogenesis Model in Wistar Rat

Barbara de Araujo Lima Dutra<sup>1,2,\*</sup>, Carolina Lyra Barreira Carneiro<sup>1</sup>, Nayanna de Oliveira Ramos Melo<sup>1</sup>, Gilson Brito de Oliveira<sup>1</sup>, Francisco Vagnaldo Fachine Jamaru<sup>1</sup>, Joao Crispim Ribeiro<sup>2,3</sup> and Conceição Aparecida Dornelas<sup>1</sup>

<sup>1</sup>Universidade Federal do Ceará, Brazil

<sup>2</sup>Instituto Cearense de Oftalmologia, Brazil

<sup>3</sup>Centro Universitário Christus, Brazil

### Article Info:

#### Keywords:

Eugenol,  
Granuloma,  
Gum arabic,  
Inflammation,  
Angiogenesis inhibitors.

#### Timeline:

Received: December 11, 2021

Accepted: March 14, 2022

Published: April 13, 2022

**Citation:** Dutra BAL, Carneiro CLB, Melo NOR, de Oliveira GB, Jamaru FVF, Ribeiro JC, Dornelas CA. Gum Arabic and Eugenol in a Silica-Induced Inflammatory Angiogenesis Model in Wistar Rat. J Pharm Nutr Sci 2022; 12: 11-19.

**DOI:** <https://doi.org/10.29169/1927-5951.2022.12.02>

\*Corresponding Author

E-mail: [barbaradutra\\_@hotmail.com](mailto:barbaradutra_@hotmail.com)

### Abstract:

This work aims to evaluate the effects of gum arabic and eugenol on inflammatory angiogenesis in a subcutaneous silica inoculum model. Ninety-six Wistar rats were distributed over 16 groups. The substances administered by gavage included distilled water, gum arabic (500 mg/100g weight), and eugenol (10mg/100g weight). Control groups received 0.2 mL of sterile distilled water subcutaneously. The experimental groups were subjected to an inoculum of 0.2 mL of silica solution (50 mg/mL) subcutaneously. For seven or 14 days, the groups received distilled water or gum arabic or eugenol or gum arabic plus eugenol. There was no difference between the histological analysis of slides stained with hematoxylin-eosin. There was a reduction in vascular density in animals that received only gum arabic for 7 ( $0.09 \mu\text{m}^2 \pm 0.02$ ) or 14 ( $0.08 \mu\text{m}^2 \pm 0.03$ ) days and only eugenol for seven days ( $0.08 \mu\text{m}^2 \pm 0.03$ ), but this was not statistically significant. The microvascular density significantly increased in the group treated with eugenol for 14 days ( $0.14 \mu\text{m}^2 \pm 0.02$ ). Eugenol reduced inflammatory angiogenesis when administered for seven days and stimulated it when administered for 14 days. Gum arabic had a potential inhibitory effect on this model. The study of inflammatory angiogenesis, induced by a silica inoculum in the subcutaneous tissue of rats, is a new and reproducible model for evaluating angiogenesis and inflammation.

© 2022 Dutra *et al.*; Licensee SET Publisher.

This is an open access article licensed under the terms of the Creative Commons Attribution License (<http://creativecommons.org/licenses/by/4.0/>) which permits unrestricted use, distribution and reproduction in any medium, provided the work is properly cited.

## INTRODUCTION

The process of angiogenesis is defined as the formation of new blood vessels by the process of germination of endothelial sprouts from pre-existing capillaries. This event is related to several physiological processes such as morphogenesis and wound healing [1]. Unregulated angiogenesis can induce or increase several pathological conditions such as chronic arthropathies, diabetic retinopathy, vascular glaucoma, tumor growth, and metastatic dissemination [2].

Inflammation is defined as the physiological response to infectious or non-infectious agents. The inflammation process is activated to remove cells from the damaged tissue and the source of injury [3]. The inflammatory process's general objective is to repair damaged tissue to restore the typical tissue architecture, thus maintaining cell/tissue homeostasis [4].

Granulomatous inflammation is a histological pattern of tissue reaction that appears after cell injury [5]. The histogenesis of granulomas depends on several cell types. Chronic inflammatory granulomatous skin diseases are mainly based on the dysfunctional negative modulation of inflammatory processes that lead to granuloma formation and maintain the formation [6].

Silicon dioxide, also known as silica, is a silicon oxide whose chemical formula is  $\text{SiO}_2$ . It can be found in many different forms. Prolonged exposure to the crystalline form of silica induces the production of chemokines, inflammatory cytokines, and growth factors [7]. These mediators have been shown to be essential for the initiation and progression of silica-induced lung diseases. In addition to these mediators, crystalline silica may induce toxicity by forming reactive oxygen species [7,8].

Cutaneous disease is a rare event characterized by a foreign body granuloma produced by accidental

implantation of silica in a wound, and the pathogenesis is unclear [7]. Some authors suggest that time is needed for this transformation considering the long characteristic period for the development of silica granuloma (mean interval of approximately ten years) [7-10].

Some plants exude natural gums as protection in response to mechanical injury or microbial invasion. Gum arabic (GA) is a naturally occurring exudate collected from Senegalese acacia [11]. GA ingestion has decreased levels of angiogenic transcription factors (angiogenin 1, angiogenin 3, and angiogenin 4) within four days. Angiogenins are related to vascular proliferation (angiogenesis) and, consequently, to the growth and metastasis of tumors and enabling vascularization of ischemic tissues [12,13].

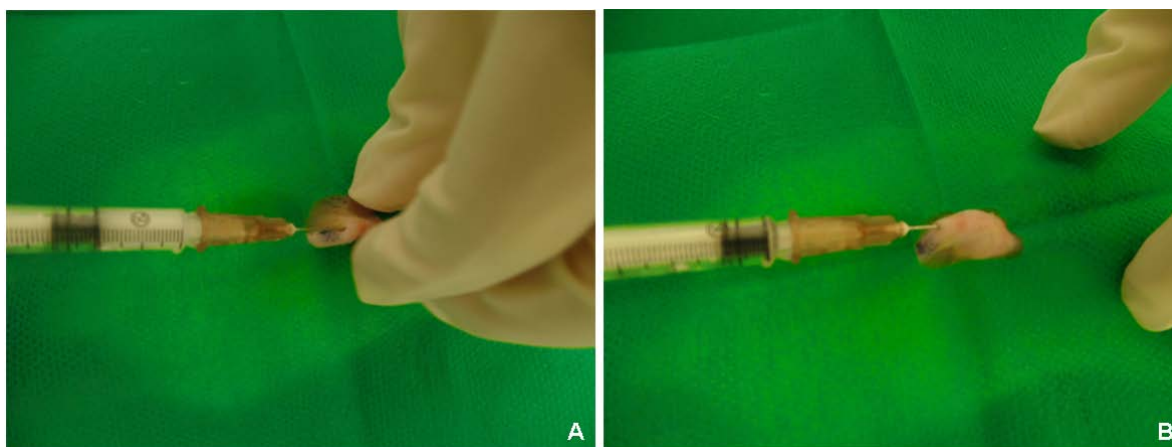
Eugenol (Eu, 4-allyl-2-methoxyphenol) and its related compounds are effective antioxidants that prevent free radical-mediated diseases such as cancer and inflammatory conditions (type 2 diabetes and cardiovascular disease), neurodegenerative disorders, and periodontal changes [14]. Depending on their nature and concentration, they can act as scavengers or free radical generators. This dual effect can influence cell viability and anti-inflammatory activity to varying degrees [15]. This study aims to evaluate the effects of gum arabic and/or eugenol on the inflammatory angiogenesis model induced by a subcutaneous silica inoculum.

## METHODS

The research project was submitted to the Ethics Committee of the Federal University of Ceará (UFC) and started after approval (CEUA nº 9407070619). 96 Wistar rats were used and distributed into 16 groups containing six animals each. Control groups (I, II, III, IV, IX, X, XI, and XII) received 0.2 mL of sterile distilled water (DW) subcutaneously in the dorsum region. The experimental groups (V, VI, VII, VIII, XIII, XIV, XV, and

**Table 1: Experimental Study Design**

SUBSTANCE	TREATMENT TIME			
	7 DAYS		14 DAYS	
	No inoculum	With inoculum	No inoculum	With inoculum
Distilled water	I	V	IX	XIII
Gum arabic + eugenol	II	VI	X	XIV
Gum arabic	III	VII	XI	XV
Eugenol	IV	VIII	XII	XVI



**Figure 1:** A. Inoculation of 0.2 mL of silica on the animal's back. B. Small bubbles formed after silica inoculation.

Source: Prepared by the authors.

XVI) were subjected to inoculation of 0.2 mL of 50 mg/mL silica solution subcutaneously in the dorsum region (Table 1).

All animals were previously submitted to intraperitoneal anesthesia, shaving, and asepsis at the inoculum site (Figure 1).

### Silica

Particles of crystalline silica silicon dioxide (400 mesh) (di Luca Distribuidora-Comercio de Minérios) were suspended in a solution of distilled water at a concentration of 50 mg/mL after sterilization (121.3 °C, 103.4 kPa for 90 min) [16].

### Gum Arabic PA (APA Comércio de Produtos Médicos Hospitalares e Laboratoriais LTDA)

The treatment was used at a 500 mg/100g of weight dose. The sample was diluted in distilled water at 5 mL/kg of weight, heated to 60 degrees, and centrifuged. It was then administered by gavage [17].

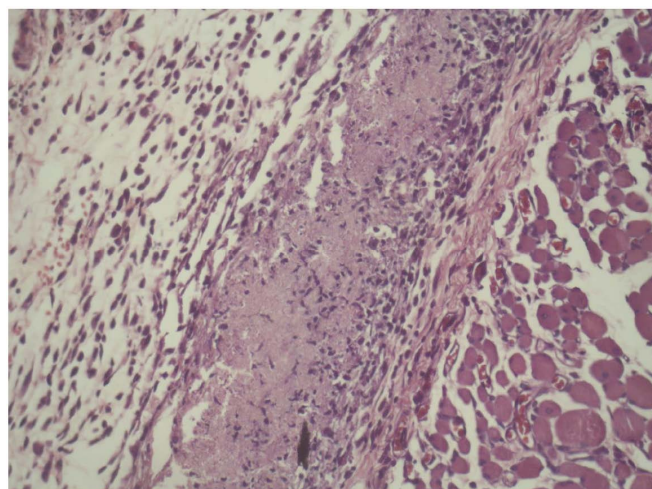
### Eugenol

The eugenol was administered by gavage at a dose of 10mg/100g weight per day [18] and carefully diluted in distilled water considering its volatility (it is an essential oil). The supplier was QUINARI Laboratory (city of Ponta Grossa/Paraná). The chemical analysis and purity analysis were performed in the organic chemistry laboratory of Professor Telma Leda (UFC).

### Microscopic Histological Evaluation

The microscopic evaluation identified foreign body granuloma, lymphocytic infiltrate, macrophage, giant

cells, plasma cells, and proliferation of fibrinoid tissue. Scores were determined (qualitative analysis) and found to correlate with their absence and presence. These variables were placed on a 0 / + / ++ scale according to the intensity of the findings [19]. An inflammatory infiltrate was considered when 50 leukocytes or more were detected in each area [20]. Quantitative analysis was performed by counting the findings in 10 fields at 400x magnification (Figure 2).

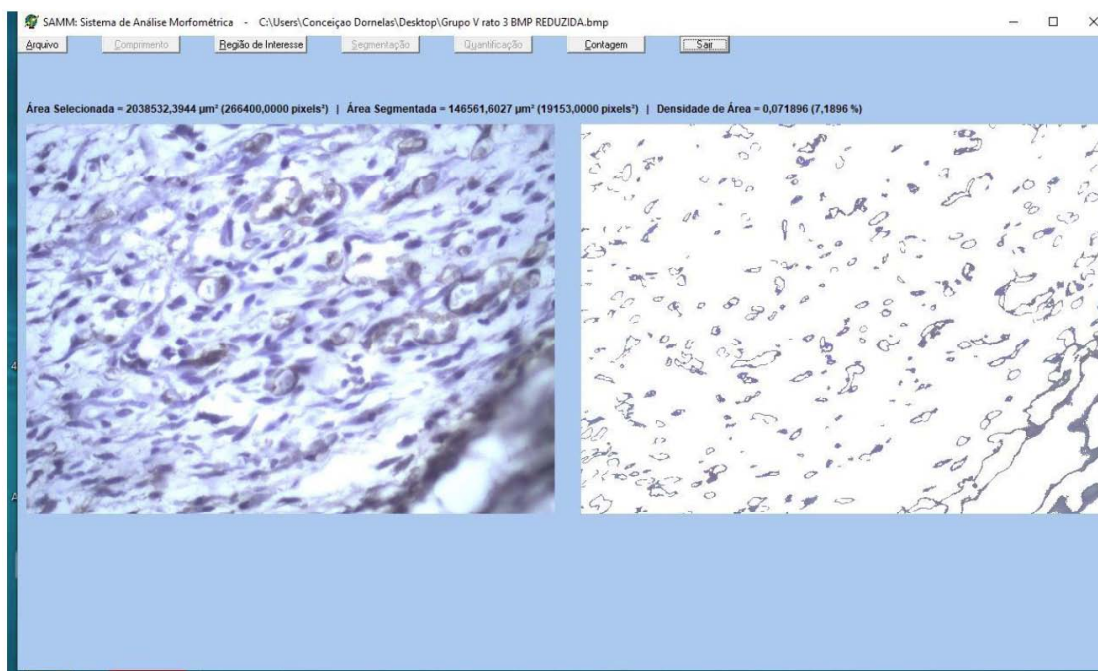


**Figure 2:** Histological section of a rat's skin and subcutaneous tissue stained with hematoxylin-eosin. This shows silica particles surrounded by vessels in the subcutaneous tissue as well as via an inflammatory infiltrate consisting of lymphocytes. There is eosinophilic fibrinoid material within this granuloma (400x magnification).

Source: Prepared by the authors.

### Quantification of Angiogenesis

Images were captured by stereoscopic microscopy and evaluated by an angiogenesis quantification system (SAMM -version 1.00-2005) to quantify angiogenesis



**Figure 3:** Morphometric Analysis System (SAMM).

Source: Prepared by the authors.

[21]. The program offers the recognition and automatic segmentation of vessels, separating them from the other components of the image. There was manual segmentation if the user found the automatic procedure to be inadequate. Next, the system provides the density of new vessels formed in relation to the segmented area (Figure 3).

### Statistical Analysis

Data were tabulated in the Statistical Package for Social Sciences (SPSS) software, version 20.0 for Windows, in which mean and standard deviation were calculated, submitted to the Shapiro-Wilk normality test, and associated with times and substances through Mann-Whitney or Kruskal-Wallis/Dunn test (non-parametric data). The level of significance was set at  $P < 0.05$ .

Analysis of variance for two classification factors was also used to assess the effects of treatments (factor 1: distilled water (DW), gum arabic (GA), eugenol (EU), and GA+EU) and time (factor 2: day 7 and day 14) on microvascular density. Bonferroni's multiple comparisons test complemented this analysis to verify differences between treatment groups at each time point as well as between the two times within each group. The data correspond to the mean and standard deviation of measurements made in six animals in each group.

### RESULTS

An experimental new model was successfully created. The formation of subcutaneous and palpable nodules can be observed at the end of the experiment.

The slides were evaluated with 400x magnification over five fields. The main histopathological features were the formation of foreign body granuloma, lymphocytic infiltrate, macrophage, giant cells, plasma cells, and proliferation of fibrous tissue. Four variables were evaluated in all groups. There was no difference between the histological findings between the groups, even on different treatment days. Only the lymphocytic infiltrate had an accentuated presence (in all groups). All other characteristics presented a slight presence regardless of the type of treatment.

According to the angiogenesis process analysis, the groups that received gum arabic had a decrease in microvascular density in relation to the control group (distilled water)—both those treated for seven days and those treated for 14 days did not occur in a statistically significant way. There was a reduction in vascular density in animals that received only eugenol for 7 days, but this was not statistically significant. Microvascular density increased statistically significantly in groups treated for 14 days. There was an increase in microvascular density in groups treated for 7 days with gum arabic + eugenol; there was a

**Table 2: Quantification of Angiogenesis through Vascular Density ( $\mu\text{m}^2$ )**

	Substance				p-Value <sup>a</sup>
	Distilled water	Gum arabic	Eugenol	Gum arabic + Eugenol	
<b>Time</b>					
7 days	0.11 ± 0.04	0.09 ± 0.02	0.08 ± 0.03	0.13 ± 0.04	0.271
14 days	0.10 ± 0.01	0.08 ± 0.03	0.14 ± 0.02*	0.09 ± 0.03	<b>0.015</b>
<b>p-Value<sup>b</sup></b>	0.486	0.413	<b>0.004</b>	0.190	

\*p < 0.05 versus other groups; Kruskal-Wallis/Dunn Test; Mann-Whitney Test; mean ± SD.

decrease in microvascular density in groups treated for 14 days. Neither change was statistically significant (Table 2).

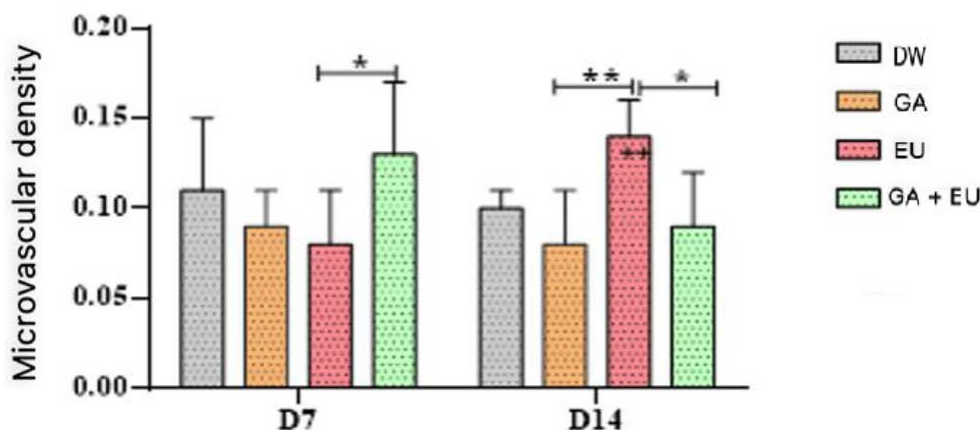
Considering the analysis of two factors, animals that received only eugenol for seven days showed a reduction in microvascular density. This reduction was statistically significant if this density was compared with the final microvascular density of the group treated with eugenol + gum arabic for 7 days. Animals treated for 14 days only with eugenol had increased microvascular density (stimulation of angiogenesis). This increase occurred with statistical significance in relation to the group treated for seven days. In comparison with animals treated with eugenol, animals treated only with GA and those treated with GA + EU for 14 days showed a statistically significant reduction in microvascular density. However, this statistical significance did not occur when comparing the microvascular density of animals treated for seven days with GA + EU and those treated for seven days only with GA. There was no statistically significant difference when comparing the microvascular density

of animals treated for 14 days with those treated with these respective substances (Figure 4).

## DISCUSSION

Our study developed a model for studying inflammatory angiogenesis. A silica inoculum was performed in the subcutaneous tissue of Wistar rats to test the effects of eugenol, gum arabic, and distilled water in the inflammatory reaction. The study of inflammatory angiogenesis induced by a silica inoculum in the subcutaneous tissue of rats is a new and reproducible model for evaluating angiogenesis and inflammation. The experimental approach used here created a model simulating a clinical condition of granulomatous inflammatory reaction resulting from the presence of a foreign body (silica).

The persistence of the harmful agent that induced inflammation upregulates the inflammatory response. A better understanding of the molecular and cellular pathways that links angiogenesis and inflammation would be helpful in developing treatment conditions in



**Figure 4:** Microvascular density measured in the treated groups distilled water (DW), gum arabic (GA), eugenol (EU), and the association of the two substances (GA+EU) on days 7 (D7) and 14 (D14).

The symbols \*(P<0.05), \*\*(P<0.01) denote statistically significant differences between the two groups marked on the same day while the symbol ++(P<0.01) indicates a statistically significant difference upon comparing day 7 in the same group (Bonferroni multiple comparisons test).

which both processes are involved [22,23]. The rationale for constructing and studying a silica-induced granuloma model was based on epidemiological studies that relate the incidence of granulomas related to occupational exposures to inorganic particles [24-26].

Silica (silicon dioxide) is very common in sand, glass, granite, mica, gravel, cement, bricks, and asbestos. It is a very common contaminant of wounds [9]. Reports on silica granulomas have already been published in the elbow biopsies as confirmed by polarized light and X-ray microanalysis, including after traffic accidents [27], head trauma from a windshield 30 years prior [20], and in children with asymptomatic placoid lesions on the face [9].

Other models aiming to create a silica granuloma have already been tested as a model of an inhaled carbon nanotube-induced granulomatous disease to simulate similarities with the pathophysiology of sarcoidosis [28]. This model had clinical efficacy but was difficult to implement. The subcutaneous silica inoculum is a low-cost and fully reproducible model. The procedure was fast and reproducible and reduced the chances of complications such as surgical site infections.

Angiogenesis was quantified via photographs (by SAMM) [21], and the microvascular density of the granuloma area was measured. Gum arabic reduced angiogenesis versus controls but did not present a statistically significant difference. Our data agree with those found in the literature [29]. There was inhibition of the levels of angiogenic transcription factors (angiogenin 1, angiogenin 3, and angiogenin 4) within four days with the use of gum arabic. This favored the reduction of vascular proliferation (angiogenesis).

We used photographs (using SAMM) to show a reduction in microvascular density in the area of the granuloma in the groups treated with eugenol for 7 days (reduction in angiogenesis), but this was not statistically significant. However, there was a statistically significant stimulation of vascular density in the groups treated for 14 days (stimulation of angiogenesis). This seems contradictory, although we know that eugenol and its compounds can act as scavengers (antioxidant substance) or generators (pro-oxidant substance) of free radicals (oxidative stress). This influences cell viability and anti-inflammatory activity to varying degrees [14].

The macrophages contribute to the production of proinflammatory cytokines and nitric oxide, which are

important for cellular and vascular events during the onset and progression of the inflammatory process. Studies have shown that eugenol can modulate macrophage functions and negatively regulate inflammation [30].

Yeh *et al.* [31] demonstrated that eugenol inhibits the inducible expression of macrophage nitric oxide synthase (iNOS) in response to LPS culminating in reducing NO levels. Eugenol also reduced TNF- $\alpha$  and IL-1  $\beta$  as well as NF- $\kappa$ B, ERK1/2, and p38 MAPK24 signaling pathways.

In macrophages, cytokines and lipopolysaccharides induce nitric synthase (iNOS) and COX-2. Both iNOS and COX-2 are responsible for producing significant proinflammatory mediators such as nitric oxide and prostaglandins in the inflammatory site. Eugenol showed an anti-inflammatory effect similar to the effects of the COX antagonist (indomethacin) and the selective COX-2 antagonist (celecoxib) [32].

The antinociceptive effects of ortho-eugenol mediated by the adrenergic system and the anti-inflammatory activity based on the regulation of proinflammatory cytokines and phosphorylation of NF- $\kappa$ B and p38 became obvious upon pre-treatment with ortho-eugenol. There were reduced writhing events and lick times in the writhing and glutamate tests, respectively. The reaction time to thermal stimulus increased significantly in the hot plate test after administration of ortho-eugenol. In anti-inflammatory tests, ortho-eugenol inhibited acetic acid-induced vascular permeability and leukocyte migration, thus reducing TNF- $\alpha$  and IL-1 $\beta$  due to its suppression of phosphorylated forms of NF- $\kappa$ B and p38 in the peritonitis test [33].

Our results corroborate these findings because we noticed an inhibition of microvascular density (anti-inflammatory/anti-angiogenic effect) when comparing the animals that received eugenol for 7 days with their respective control (not statistically significant). There was higher microvascular density (inflammatory/angiogenic stimulus) versus the granulomas of animals that received eugenol for 14 days. These results, although antagonistic, as we have seen previously, have already been described. That is, eugenol and its compounds can act as scavengers (antioxidant substance) or generators (pro-oxidant substance) of free radicals (oxidative stress). We could have used longer experiments, but the time required for angiogenic stimulation is certainly within 14 days, as shown via statistical analysis.

Eugenol has beneficial activities for cells, but it can also be toxic depending on the type of cell to which it is exposed and the concentration used. Thus, eugenol toxicity was observed in human dental pulp fibroblasts with DNA damage. Eugenol could induce genotoxicity of mouse peritoneal macrophages, but it also has antigenotoxic potential depending on the treatment protocol. These may be interlinked with its effect on drug metabolism. Therefore, eugenol can modulate inflammatory and oxidative processes, but it must be used safely [30].

Although toxicity has been studied *in vivo*, little or no information is available on human subjects. The pro-oxidant effect of eugenol mediates its toxicity attributed to protein inactivation due to the binding of eugenol to lysine residues. Its cytotoxicity is probably due to its active metabolic reactions that react with DNA, thus forming adducts that can destroy nuclear genetic material. However, the World Health Organization (WHO) declared eugenol a non-mutant molecule and generally recognized as safe [34].

Oral ingestion of eugenol by Wistar rats in different doses over a 15-day period may cause some changes in blood chemistry. Furthermore, eugenol increases the levels of aspartate aminotransferase, alanine aminotransferase, and total bilirubin, but these effects are not dose-dependent [35]. Thus, there is a limit on the dose and the time to obtain a therapeutic or toxic effect of any drug.

Although there are many study articles on the cytotoxic properties of eugenol [36-40], the controversial results in the literature make it difficult to interpret efficacy and safety. However, the ability of eugenol to induce oxidative stress (inflammation), as observed, seems to be related to its cytotoxicity and antitumor effects [18, 41].

Problems related to the degree of purity of the compound, its evaporation during the experiments, and the various methods used to quantify these data (different models and animals can present divergent results and interpretations) can all partially explain these controversial results.

There are no reports in the literature about the association of gum arabic with eugenol. We found an increase in microvascular density in the groups treated for seven days with gum arabic and eugenol. There was a reduction in microvascular density in the groups treated for 14 days. However, neither of these changes were statistically significant.

## CONCLUSION

A new inflammatory model was successfully created. Eugenol reduced angiogenesis in the groups treated for 7 days but not in a statistically significant way. Angiogenesis was stimulated in groups treated for 14 days. Although gum arabic did not inhibit angiogenesis with statistical significance, there was no increase in vascular density in animals treated only with GA. Then, gum arabic had a potential inhibitory effect on this inflammatory angiogenesis model. There was no difference between the findings of inflammatory cells regardless of the substance or time of treatment. Gum arabic had a potential inhibitory effect on this inflammatory angiogenesis model.

## AUTHOR CONTRIBUTIONS

All authors contributed to the experiment and the writing of the manuscript.

## CONFLICT OF INTERESTS

No author has a proprietary interest in any material or method mentioned.

## ACKNOWLEDGEMENTS

Research was supported by an institutional grant from Coordenação de Aperfeiçoamento de Pessoal de Nível Superior (CAPES) / Fundação Cearense de Apoio ao Desenvolvimento Científico e Tecnológico (FUNCAP), notice 04/2017, No 88887.165958/2018-00, Brazil.

Research performed at Postgraduate Program in Pathology, Laboratory of Experimental Surgery and Nucleus of Research and Development of Medicines, Laboratory of Pharmacology and Preclinical Research, Medical School, Universidade Federal do Ceará (UFC), Fortaleza-CE, Brazil. Part of Master's degree thesis. Tutor: Profa. Conceição Aparecida Dornelas.

## REFERENCES

- [1] Johnson LV, *et al.* Activation and inflammatory processes in Drusen formation and age related macular degeneration. *Exp Eye Res* 2001; 73(6): 887-96. <https://doi.org/10.1006/exer.2001.1094>
- [2] Sajib S, *et al.* Mechanisms of angiogenesis in microbe-regulated inflammatory and neoplastic conditions. *Angiogenesis* 2018; 21(1): 1-14. <https://doi.org/10.1007/s10456-017-9583-4>
- [3] Aguilar-Cazares D, *et al.* Contribution of angiogenesis to inflammation and cancer. *Frontiers in Oncology* 2019; 9: 1399. <https://doi.org/10.3389/fonc.2019.01399>

- [4] Varela ML, *et al.* Acute inflammation and metabolism. *Inflammation* 2018; 41(4): 1115-1127. <https://doi.org/10.1007/s10753-018-0739-1>
- [5] Shah K, Pritt B, Alexander M. Histopathologic review of granulomatous inflammation. *Journal of Clinical Tuberculosis and Other Mycobacterial Diseases* 2017; 7: 1-12. <https://doi.org/10.1016/j.jctube.2017.02.001>
- [6] Von Stebut E, *et al.* Early macrophage influx to sites of cutaneous granuloma formation is dependent on MIP-1 $\alpha$ / $\beta$  released from neutrophils recruited by mast cell-derived TNF $\alpha$ . *Blood, The Journal of the American Society of Hematology* 2003; 101(1): 210-215. <https://doi.org/10.1182/blood-2002-03-0921>
- [7] Ferreira  $\dot{A}$ S, *et al.* Fibrose maciça progressiva em trabalhadores expostos à sílica: achados na tomografia computadorizada de alta resolução. *Jornal Brasileiro de Pneumologia [online]* 2006; 32(6): [Acessado 28 Fevereiro 2022], pp. 523-528. <https://doi.org/10.1590/S1806-37132006000600009>
- [8] Castranova V. Signaling pathways controlling the production of inflammatory mediators in response to crystalline silica exposure: Role of reactive oxygen/nitrogen species. *Free Radical Biology and Medicine* 2004; 37(7): 916-925. <https://doi.org/10.1016/j.freeradbiomed.2004.05.032>
- [9] Kaya TI, *et al.* Cutaneous silica granuloma in a child. *Pediatric Dermatology* 2003; 20(1): 40-43. <https://doi.org/10.1046/j.1525-1470.2003.03009.x>
- [10] Mowry RG, Sams WM, Caulfield JB. Cutaneous sílica granuloma. *Arch Dermatol* 1991; 127: 692-694. <https://doi.org/10.1001/archderm.1991.01680040100011>
- [11] Kaddam LA, Kaddam AS. Effect of Gum Arabic (Acacia senegal) on C-reactive protein level among sickle cell anemia patients. *BMC Res Notes* 2020; 13(1): 162. <https://doi.org/10.1186/s13104-020-05016-2>
- [12] Nasir O, *et al.* Downregulation of angiogenin transcript levels and inhibition of colonic carcinoma by Gum Arabic (Acacia senegal). *Nutrition and Cancer* 2010; 62(6): 802-810. <https://doi.org/10.1080/01635581003605920>
- [13] Avelino ALN, *et al.* Antioxidant and Antigenotoxic Actions of Gum Arabic on the Intestinal Mucosa, Liver and Bone Marrow of Swiss Mice Submitted to Colorectal Carcinogenesis. *Nutrition and Cancer* 2021; 4: 1-9.
- [14] Prakash PAGN, Gupta N. Therapeutic uses of Ocimum sanctum Linn (Tulsi) with a note on eugenol and its pharmacological actions: a short review. *Indian Journal of Physiology and Pharmacology* 2005; 49(2): 125.
- [15] Carreras A, *et al.* Punicalagin and catechins contain polyphenolic substructures that influence cell viability and can be monitored by radical chemosensors sensitive to electron transfer. *Journal of Agricultural and Food Chemistry* 2012; 60(7): 1659-1665. <https://doi.org/10.1021/jf204059x>
- [16] Zhang L, *et al.* Polymer-Brush-Grafted Mesoporous Silica Nanoparticles for Triggered Drug Delivery. *Chemphyschem* 2018; 19(16): 1956-1964. <https://doi.org/10.1002/cphc.201800018>
- [17] Nasif WA, Loffy M, Mahmoud MR. Protective effect of gum acacia against the aspirin induced intestinal and pancreatic alterations. *Eur Rev Med Pharmacol Sci* 2011; 15(3): 285-92.
- [18] Bezerra DP, *et al.* The Dual Antioxidant/Prooxidant Effect of Eugenol and Its Action in Cancer Development and Treatment. *Nutrients* 2017; 9(12): 1367. <https://doi.org/10.3390/nu9121367>
- [19] Lockwood DNJ, *et al.* The histological diagnosis of leprosy type 1 reactions: identification of key variables and an analysis of the process of histological diagnosis. *Journal of Clinical Pathology* 2008; 61(5): 595-600. <https://doi.org/10.1136/jcp.2007.053389>
- [20] Michailowsky V, *et al.* Pivotal role of interleukin-12 and interferon- $\gamma$  axis in controlling tissue parasitism and inflammation in the heart and central nervous system during *Trypanosoma cruzi* infection. *The American Journal of Pathology* 2001; 159(5): 1723-1733. [https://doi.org/10.1016/S0002-9440\(10\)63019-2](https://doi.org/10.1016/S0002-9440(10)63019-2)
- [21] Fachine-Jamacaru FV, Fachine Júnior JU, de Moraes Filho MO. Modelo de angiogênese inflamatória em córnea de coelho induzida pela cauterização alcalina pontual [Model of inflammatory angiogenesis in rabbit cornea induced by punctual alkaline cauterization]. *Acta Cir Bras* 2005; 20(1): 64-73. <https://doi.org/10.1590/S0102-86502005000100010>
- [22] Lockwood DNJ, *et al.* The histological diagnosis of leprosy type 1 reactions: identification of key variables and an analysis of the process of histological diagnosis. *Journal of Clinical Pathology* 2008; 61(5): 595-600. <https://doi.org/10.1136/jcp.2007.053389>
- [23] Michailowsky V, *et al.* Pivotal role of interleukin-12 and interferon- $\gamma$  axis in controlling tissue parasitism and inflammation in the heart and central nervous system during *Trypanosoma cruzi* infection. *The American Journal of Pathology* 2001; 159(5): 1723-1733. [https://doi.org/10.1016/S0002-9440\(10\)63019-2](https://doi.org/10.1016/S0002-9440(10)63019-2)
- [24] Guarnieri G, Bizzotto R, Gottardo O, Velo E, Cassaro M, Vio S, Putzu MG, Rossi F, Zuliani P, Liviero F, Mason P, Maestrelli P. Multiorgan accelerated silicosis misdiagnosed as sarcoidosis in two workers exposed to quartz conglomerate dust. *Occup Environ Med* 2019; 76(3): 178-180. <https://doi.org/10.1136/oemed-2018-105462>
- [25] Baur X, Sanyal S, Abraham JL. Mixed-dust pneumoconiosis: Review of diagnostic and classification problems with presentation of a work-related case. *Sci Total Environ* 2019; 652: 413-421. <https://doi.org/10.1016/j.scitotenv.2018.10.083>
- [26] Norlén F, Gustavsson P, Wiebert P, Rylander L, Albin M, Westgren M, Plato N, Selander J. Occupational exposure to inorganic particles during pregnancy and birth outcomes: a nationwide cohort study in Sweden. *BMJ Open* 2019. <https://doi.org/10.1136/bmjopen-2018-023879>
- [27] Newman LS, *et al.* Um estudo etiológico caso-controle da sarcoidose: Fatores de risco ocupacionais e ambientais. *Sou J Respir Crit Care Med* 2004; 170: 1324-1330. <https://doi.org/10.1164/rccm.200402-249OC>
- [28] Onesti MG, *et al.* A clinical case of cutaneous silica granuloma. *Giornale italiano di dermatologia e venereologia: organo ufficiale. Societa italiana di dermatologia e sifilografia* 2014; 149(3): 376-378.
- [29] Pimentel L, *et al.* Simultaneous presentation of silicone and silica granuloma. *Dermatology* 2002; 205(2): 162-165. <https://doi.org/10.1159/000063897>
- [30] Barna BP, Malur A, Thomassen MJ. Studies in a Murine Granuloma Model of Instilled Carbon Nanotubes: Relevance to Sarcoidosis. *Int J Mol Sci* 2021; 22(7): 3705. <https://doi.org/10.3390/ijms22073705>
- [31] Yeh JL, *et al.* Eugenolol and glyceryl-isoegenol suppress LPS-induced iNOS expression by down-regulating NF- $\kappa$ B AND AP-1 through inhibition of MAPKS and AKT/IkappaBalpha signaling pathways in macrophages. *Int J Immunopathol Pharmacol* 2011; 24(2): 345-56. <https://doi.org/10.1177/039463201102400208>
- [32] Nasir O, *et al.* Downregulation of angiogenin transcript levels and inhibition of colonic carcinoma by Gum Arabic (Acacia senegal). *Nutrition and Cancer* 2010; 62(6): 802-810. <https://doi.org/10.1080/01635581003605920>
- [33] Barboza JN, da Silva Maia Bezerra Filho C, Silva RO, Medeiros JVR, de Sousa DP. An Overview on the Anti-inflammatory Potential and Antioxidant Profile of Eugenol. *Oxid Med Cell Longev* 2018. <https://doi.org/10.1155/2018/3957262>



- [34] Gorrini C, Harris IS, Mak TW. Modulation of oxidative stress as an anticancer strategy. *Nat Rev Drug Discov* 2013; 12: 931-947. <https://doi.org/10.1038/nrd4002>
- [35] Fonsêca DV, *et al.*, Ortho-eugenol exhibits anti-nociceptive and anti-inflammatory activities. *Int Immunopharmacol* 2016; 38: 402-408. <https://doi.org/10.1016/j.intimp.2016.06.005>
- [36] Nisar MF, *et al.* Pharmacological Properties and Health Benefits of Eugenol: A Comprehensive Review *Oxid Med Cell Longev* 2021. <https://doi.org/10.1155/2021/2497354>
- [37] Chaieb K, Hajlaoui H, Zmantar T, Kahla-Nakbi AB, Rouabhia M, Mahdouani K, Bakhrouf A. The chemical composition and biological activity of clove essential oil, *Eugenia caryophyllata* (*Syzygium aromaticum* L. Myrtaceae): a short review. *Phytother Res* 2007; 21(6): 501-6. <https://doi.org/10.1002/ptr.2124>
- [38] Ranjitkar S, Zhang D, Sun F, Salman S, He W, Venkitanarayanan K, Tulman ER, Tian X. Cytotoxic effects on cancerous and non-cancerous cells of trans-cinnamaldehyde, carvacrol, and eugenol. *Sci Rep* 2021; 11; 11(1). <https://doi.org/10.1038/s41598-021-95394-9>
- [39] Alves TA, Pinheiro PF, Praça-Fontes MM, Andrade-Vieira LF, Lourenço MP, Lage MR, Alves TA, Cruz FA, Carneiro JWM, Ferreira A, Soares TCB. Bioactivity and molecular properties of Phenoxyacetic Acids Derived from Eugenol and Guaiacol compared to the herbicide 2,4-D. *An Acad Bras Cienc* 2021; 93(4). <https://doi.org/10.1590/0001-3765202120191368>
- [40] Fuentes C, Ruiz-Rico M, Fuentes A, Barat JM, Ruiz MJ. Comparative cytotoxic study of silica materials functionalised with essential oil components in HepG2 cells. *Food Chem Toxicol* 2021. <https://doi.org/10.1016/j.fct.2020.111858>
- [41] Ma L, Liu J, Lin Q, Gu Y, Yu W. Eugenol protects cells against oxidative stress via Nrf2. *Exp Ther Med* 2021; 21(2): 107. <https://doi.org/10.3892/etm.2020.9539>